

Evaluation of Acute Appendicitis by Pediatric Emergency Physician Sonography

Adam B. Sivitz, MD*; Stephanie G. Cohen, MD; Cena Tejani, MD

*Corresponding Author. E-mail: asivitz@barnabashealth.org.

Study objective: We investigate the accuracy of pediatric emergency physician sonography for acute appendicitis in children.

Methods: We prospectively enrolled children requiring surgical or radiology consultation for suspected acute appendicitis at an urban pediatric emergency department. Pediatric emergency physicians performed focused right lower-quadrant sonography after didactics and hands-on training with a structured scanning algorithm, including the graded-compression technique. We compared their sonographic interpretations with clinical and radiologic findings, as well as clinical outcomes as defined by follow-up or pathologic findings.

Results: Thirteen pediatric emergency medicine sonographers performed 264 ultrasonographic studies, including 85 (32%) in children with pathology-verified appendicitis. Bedside sonography had a sensitivity of 85% (95% confidence interval [CI] 75% to 95%), specificity of 93% (95% CI 85% to 100%), positive likelihood ratio of 11.7 (95% CI 6.9 to 20), and negative likelihood ratio of 0.17 (95% CI 0.1 to 0.28).

Conclusion: With focused ultrasonographic training, pediatric emergency physicians can diagnose acute appendicitis with substantial accuracy. [Ann Emerg Med. 2014;64:358-364.]

Please see page 359 for the Editor's Capsule Summary of this article.

A **feedback** survey is available with each research article published on the Web at www.annemergmed.com.

A **podcast** for this article is available at www.annemergmed.com.

0196-0644/\$-see front matter

Copyright © 2014 by the American College of Emergency Physicians.

<http://dx.doi.org/10.1016/j.annemergmed.2014.03.028>

INTRODUCTION

Although the classic appendicitis presentation of migratory right lower quadrant pain associated with nausea and vomiting and progressing to rebound tenderness is well described, the real-time clinical diagnosis is often elusive.¹⁻³ Computed tomography (CT) and ultrasonography are increasingly part of the evaluation,⁴⁻⁶ with the former raising concerns about radiation exposure.⁷ Accordingly, ultrasonography is advocated as the first-line imaging strategy for children by the American College of Radiology.^{8,9}

Sonography of the acute abdomen is supported by the 2008 American College of Emergency Physicians ultrasonographic policy statement,¹⁰ as well as pediatric emergency medicine fellow training guidelines for ultrasonography.¹¹ Recent studies have shown promising results for pediatric emergency medicine sonography of intussusception and pyloric stenosis.^{12,13} Conflicting results have been observed with appendicitis.^{14,15} The ability to accurately and quickly identify surgical pathologies is a critical need for pediatric emergency physicians, who may not have access to formal radiology ultrasonographic services around the clock. Rapid identification of acute appendicitis would also likely improve patient throughput, avoid unnecessary reliance on CTs, and minimize treatment delays.

Importance

Pediatric emergency medicine sonography, if accurate, could likely minimize treatment delays and avoid unnecessary reliance on CT scanning.

Goals of This Investigation

We wished to determine the accuracy of pediatric emergency medicine sonography for acute appendicitis compared with the reference standards of surgical pathology or clinical outcome. Our secondary goal was to compare pediatric emergency medicine ultrasonography to radiology ultrasonography, pretest clinical suspicion, and sonographer confidence.

MATERIALS AND METHODS

Study Design, Setting, and Selection of Participants

This was a prospective observational study conducted between August 2009 and May 2012 at an academic urban teaching hospital with an annual pediatric volume of 30,000 patients. The hospital's institutional review board approved the study, and informed consent was obtained from parents, with assent from minors older than 7 years.

Editor's Capsule Summary*What is already known on this topic*

Ultrasonography is the recommended first-line imaging modality for children with suspected appendicitis.

What question this study addressed

Can emergency physicians learn to perform bedside ultrasonography for suspected appendicitis?

What this study adds to our knowledge

After focused training, 13 sonographers studied 264 children with suspected appendicitis, of whom 32% ultimately had the disease. Physician sensitivity and specificity were high: 85% and 93%, respectively.

How this is relevant to clinical practice

Emergency physicians can learn to accurately use ultrasonography to evaluate children with suspected appendicitis.

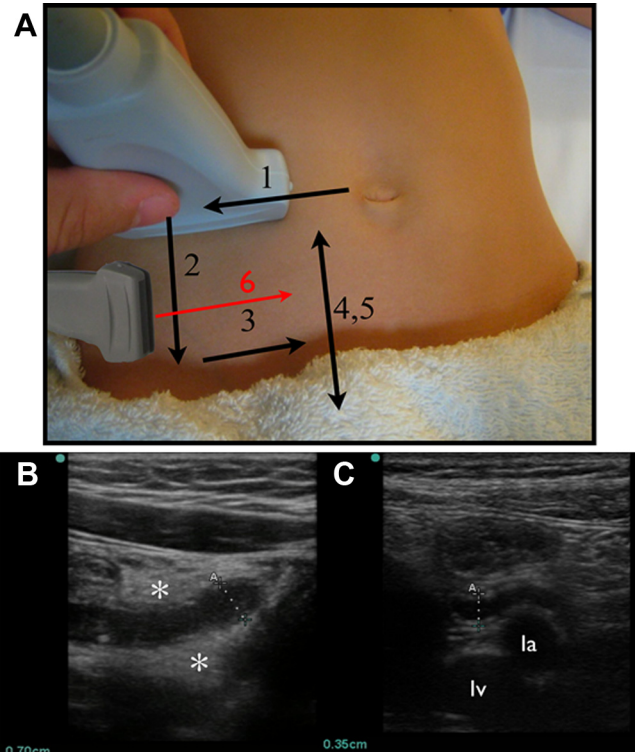


Figure 1. Ultrasonographic scanning protocol. A, With the probe initially in the transverse position at the level of the umbilicus and using compression, (1) move laterally to identify the lateral border of the ascending colon. (2) Move down the lateral border to the end of the cecum. (3) Move medially across the psoas and iliac vessels. (4, 5) Move down and up the border of the cecum. (6) With the probe in a sagittal position, identify the end of the cecum in the long axis and move medially across the psoas. B, Inflamed, dilated appendix (calipers A) with surrounding periappendiceal inflammation (*). C, Normal appendix (calipers A) overlying the la and lv. la, Iliac artery; lv, iliac vein.

We enrolled children presenting or transferred to our emergency department (ED) with a clinical suspicion for acute appendicitis at any time of day when a study sonographer was available. Our treating physicians do not use clinical scoring algorithms for appendicitis. If study imaging would have caused a delay, it was performed immediately after completion of the radiology study, with the study sonographer blinded to the radiologic findings. We excluded children with previous abdominal surgery, a need for critical care, or those transferred from another facility with definitive imaging for acute appendicitis. We excluded from our final analysis examinations with incomplete data. To identify all eligible children who were not enrolled, we cross-checked radiology logs for abdominal CT and appendiceal ultrasonographic results and searched ED electronic medical records for the term “appendicitis.”

Our study sonographers were a pediatric emergency medicine faculty physician and 12 pediatric emergency medicine fellows, the latter with no previous experience with bowel sonography. The faculty sonographer, although not fellowship trained in ultrasonography or a Registered Diagnostic Medical Sonographer, had 4 years’ and greater than 1,000 scans’ worth of bedside ultrasonographic experience, including 50 appendicitis ultrasonographic evaluations.

The faculty physician gave a 45-minute lecture to the fellows and then supervised each of them in 5 practice examinations with a Sonosite (Bothell, WA) M-Turbo, using a 10-8 MHz linear or a 5-3 MHz curvilinear probe. The scanning protocol (Figure 1A; Video E1, available online at <http://www.annemergmed.com>) recognized that the appendix may be found in a variety of locations.¹⁶ Starting in the transverse plane at the level of the

umbilicus and with the graded compression technique,¹⁷ the probe was moved laterally, identifying the ascending colon and lateral abdominal wall. The colon was traced proximally into the iliac fossa. The transducer was then moved across the psoas muscle to the psoas’s medial border, identifying the immediately adjacent iliac artery and vein. With the psoas and iliac vessels kept in view, the transducer traced down into the pelvis and then back toward the umbilicus. If the appendix had not yet been identified, the transducer was rotated into the sagittal plane and placed over the lateral portion of the cecal fossa, ideally over the cecum. Then, the transducer was swept medially, compressing the cecum against the psoas muscle. In the case of well-localized pain, the sonographer could also start at the point of maximal tenderness as directed by the patient.

Methods of Measurement

The sonographer recorded appendiceal visualization or nonvisualization, compressibility, maximum diameter, and

evidence of periappendiceal inflammation. A tubular, noncompressible, aperistaltic structure in the right lower quadrant, greater than 6 mm in diameter, was considered diagnostic^{18,19}; however, the examiner's assessment could also include secondary findings (eg, the presence of an appendicolith, free fluid, periappendiceal inflammation).²⁰ Visualization of an appendix less than 6 mm in diameter or nonvisualization without secondary signs of inflammation was considered a normal study result.^{21,22} A sonographic McBurney's sign was considered present with pain on compression of a visualized appendix. Sonographers graded their confidence in their findings with a 100-mm visual analog scale (VAS), with 0 being no confidence and 100 total confidence.

Treating physicians recorded presenting signs and symptoms, illness duration, and the clinical likelihood of appendicitis by VAS (0 not present, 100 certainly present) on a standardized data collection sheet. We blinded treating physicians to sonographic findings. When the study sonographer was also the treating physician, management and imaging decisions were made before study sonography, with continuing management based on surgical and radiologic consultant recommendations.

We made follow-up telephone calls no sooner than 1 week and up to 6 months after the ED visit for children who did not have pathologic specimens for review. If follow-up was unavailable by telephone, the electronic medical records were checked up to 1 year after the initial ED visit for any further visits to the medical center, including ED visits or operative reports.

To assess agreement, each sonographic examination was later reviewed by the lead pediatric emergency medicine sonologist (A.B.S.) and a pediatric radiologist blinded to the clinical findings and original impression. Images were blinded by digitally cropping and removing time and date identifiers.

Primary Data Analysis

The data were entered into Excel (Microsoft, Redmond, WA) and analyzed with SAS (version 9.3; SAS Institute, Inc., Cary, NC). Our primary unit of analysis is the sonographic study, although we report patient- and visit-related data at the patient level. To address clustering by sonographer, we assessed the intraclass lack of independence, using a mixed general linear model. The random-effects portion of the result yielded a variance-covariance matrix that was used to measure the covariate contribution to the intraclass variance. We calculated test characteristics and their 95% confidence intervals (CIs) while controlling for clustering. We used κ to report intraobserver agreement.

Given a historical incidence of appendicitis of 30%, a sensitivity of 95%, a specificity of 90%, and a desired absolute CI width of 0.05, we determined to enroll a sample size of 243 studies.²³

RESULTS

Characteristics of Study Subjects

Of the 254 enrolled subjects (Figure 2), we had reference standard pathologic findings or follow-up available for 231 (91%). These children had a median age of 10.2 years (range 2 to

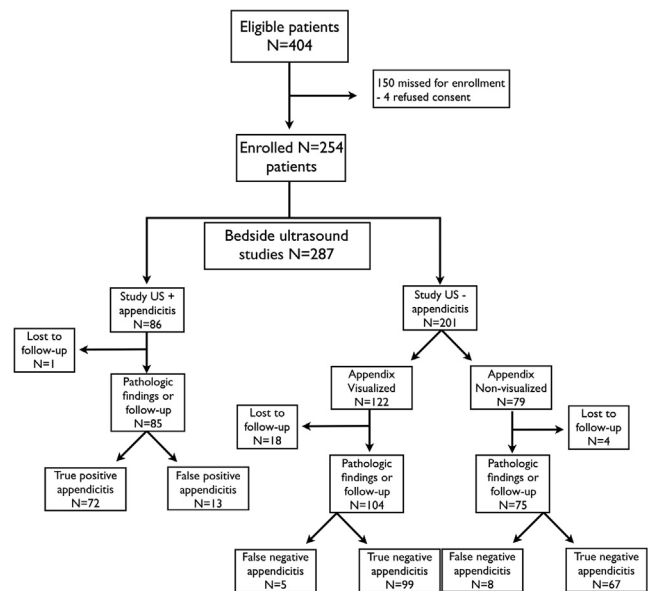


Figure 2. Study flow chart.

20.9 years), and 53% were male children. Demographics and clinical findings were generally similar between the analyzed and missed groups (Table 1).

Twenty-three patients were lost to follow-up, ie, we could not reach them by telephone and they had no return visits to our hospital.

Seventy-six children had pathology findings positive for acute appendicitis (prevalence 33%). There were 4 negative appendectomy results (all with negative pediatric emergency medicine sonography results) and no cases of missed appendicitis. We contrast findings for patients with and without appendicitis (Table 2).

Main Results

Thirteen pediatric emergency medicine sonographers performed 287 sonographic examinations, with reference standard pathologic findings or follow-up available in 264 for final analysis. Sonographers performed a median of 19 scans (interquartile range (IQR) 7 to 47) per sonographer. Study ultrasonographic examinations were completed in a median of 104 minutes (range -235 to 857 minutes) before the final radiology imaging, with only 2 patients taken to the operating room without some form of formal radiology imaging.

Compared with our reference standard, the sensitivity of pediatric emergency medicine ultrasonography was 85% (95% CI, 75% to 95%), specificity 93% (95% CI, 85% to 100%), positive likelihood ratio (LR+) 11.7 (95% CI, 6.9 to 20), and negative likelihood ratio (LR-) 0.16 (95% CI, 0.1 to 0.27). Contrast by sonographer is shown in Figures 3 and Figure E1. The most experienced sonographer performed 113 studies, with a sensitivity of 89% (95% CI, 83% to 95%), specificity of 99% (95% CI, 97% to 100%), LR+ 68 (9.8 to 481), and LR- 0.11 (0.07 to 0.17). When excluding the most experienced sonographer, the remainder of our physicians performed 151

Table 1. Patient demographics and clinical characteristics in the enrolled and missed for enrollment populations.

Characteristics	Enrolled (N=231)	Missed (N=150)	Difference (95% CI)
Age, median (IQR), y	10.3 (7.8 to 16.1)	9.8 (7.8 to 14.6)	0.5 (-0.6 to 1.2)
Sex, male, % (95% CI)	60 (53 to 66)	49 (41 to 57)	11 (-3 to 25)
Symptom duration, median (IQR), h	24 (12 to 48)	24 (12 to 72)	-0.2 (-6 to 0)
Fever, % (95% CI)	27 (22 to 33)	38 (31 to 46)	-11 (-27 to 6)
Nausea, % (95% CI)	67 (60 to 72)	42 (35 to 51)	25 (11 to 39)
Vomiting, % (95% CI)	63 (57 to 69)	59 (51 to 67)	4 (-8 to 17)
Rebound, % (95% CI)	35 (29 to 41)	12 (8 to 18)	23 (4.3 to 41)
RLQ tenderness, % (95% CI)	94 (90 to 96)	86 (80 to 91)	8 (1.2 to 14)
Migratory pain, % (95% CI)	38 (32 to 45)	25 (19 to 33)	13 (-2 to 30)
Cough/hop pain, % (95% CI)	43 (38 to 50)	19 (13 to 25)	24 (7 to 42)
Anorexia, % (95% CI)	57 (50 to 64)	27 (21 to 35)	30 (15 to 47)
WBC cells, median (IQR), $\times 10^3/\mu\text{L}$	10.9 (7.1 to 14.9)	10.4 (7.5 to 14.1)	0.5 (-0.7 to 1.7)
Appendicitis, % (95% CI)	33 (28 to 39)	27 (20 to 34)	5 (-11 to 23)

IQR, Interquartile range; RLQ, right lower quadrant; WBC, white blood cells.

studies, with a sensitivity of 82% (95% CI, 69% to 94%), specificity 88% (95% CI, 79% to 97%), LR+ 6.9 (95% CI, 4 to 12), and LR- 0.21 (95% CI, 0.12 to 0.38). The within-class correlation coefficient was 0 (95% CI -0.1 to 0.12). Sonographers' median VAS confidence in their findings was 85% (IQR 67 to 95), with test characteristics stratified by VAS confidence quartile in Table E1, available online at <http://www.annemergmed.com>.

The study sonographer indicated visualizing the appendix in 189 studies (71%, 95% CI, 65% to 77%). In these cases, the sensitivity was 95% (95% CI, 86% to 100%), specificity 88% (95% CI, 80% to 97%), LR+ 8.2 (95% CI, 4.9 to 13.8), and LR- 0.06 (95% CI, 0.02 to 0.15).

Of the 75 studies with a nonvisualized appendix, 8 were ultimately positive for appendicitis. Six of these 8 also had radiology sonography, with visualization achieved in only one. In the 56 studies in nonappendicitis patients with concurrent radiology ultrasonography, the radiology examination identified an appendix in 11, with 2 incorrectly classified as positive studies.

Test characteristics were similar when stratified by experience (Table E2, available online at <http://www.annemergmed.com>). Of the 4 false-negative studies in our sample performed after a sonographer's 25th study, the first was challenged by the patient's body habitus, the second was discontinued after 30 seconds because of discomfort, and the remaining 2 had visualized

Table 2. Demographic, clinical, and sonographic characteristics for patients with and without appendicitis.

Characteristics	Appendicitis (N=76)	No Appendicitis (N=155)	Difference (95% CI)
Age, median (IQR), y	10.8 (7.8 to 15.5)	10.8 (7.8 to 16)	0 (-1.4 to 1.5)
Sex, male (95% CI), %	69 (59 to 79)	54 (46 to 62)	15 (-1.3 to 33)
Symptom duration, median (IQR), h	24 (12 to 39)	24 (12 to 72)	0 (-10 to 0)
Fever (95% CI), %	26 (18 to 37)	28 (21 to 35)	-2 (-0.25 to 0.22)
Nausea (95% CI), %	74 (63 to 82)	63 (55 to 70)	11 (-4.3 to 25)
Vomiting (95% CI), %	74 (63 to 82)	58 (50 to 65)	16 (-0.1 to 30)
Rebound (95% CI), %	62 (51 to 72)	21 (16 to 29)	41 (21 to 61)
RLQ tenderness (95% CI), %	96 (89 to 99)	92 (86 to 95)	4 (-2 to 10)
Migratory pain (95% CI), %	50 (39 to 61)	32 (25 to 40)	18 (-3 to 38)
Cough/hop pain (95% CI), %	65 (53 to 74)	34 (27 to 41)	31 (13 to 50)
Anorexia (95% CI), %	74 (63 to 82)	49 (41 to 56)	25 (8.8 to 41)
WBC cells, median (IQR), $\times 10^3/\mu\text{L}$	14.2 (11.8 to 18.4)	8.4 (6.4 to 12.2)	5.8 (4.2 to 6.8)
WBC left shift (95% CI), %	84 (74 to 91)	45 (37 to 52)	40 (25 to 55)
WBC >10,000 cells/ μL (95% CI), %	86 (76 to 92)	36 (29 to 44)	50 (35 to 65)
ANC, median (IQR)	11,300 (9,750 to 16,065)	5,900 (3,600 to 9,800)	5,400 (4,332 to 6,850)
ANC <6,750 (95% CI), %	9 (5 to 18)	57 (50 to 65)	48 (24 to 72)
Urine ketones (95% CI), %	37 (27 to 48)	25 (18 to 32)	12 (-10 to 35)
Clinical VAS, median (IQR)	80 (67 to 93)	41 (24.5 to 64)	39 (26 to 41)
Sonographic findings	Appendicitis (N=85)	No appendicitis (N=179)	
Sonographic McBurney's sign (95% CI), %	85 (76 to 91)	30 (23 to 37)	55 (37 to 72)
Periappendiceal inflammation (95% CI), %	73 (63 to 81)	8 (5 to 13)	65 (48 to 84)
Free fluid (95% CI), %	32 (23 to 42)	7 (4 to 11)	25 (2.2 to 48)
Compressibility (95% CI), %	2 (0.6 to 8)	12 (8-17)	10 (-13 to 34)

ANC, Absolute neutrophil count.

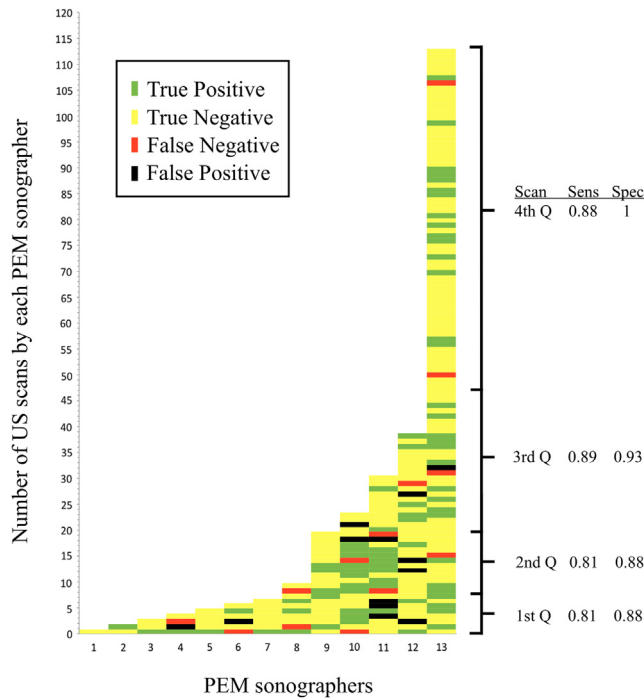


Figure 3. Diagnostic results for each pediatric emergency medicine sonographic study compared with the reference standard of surgical pathology or clinical follow-up. Each block represents a sonographic study performed by each pediatric emergency physician sonographer (x axis) and is color coded to show the test result. The blocks are arranged vertically in chronological order, with the first scan at the bottom. The sensitivity and specificity are listed for each quartile of scans performed by the pediatric emergency physicians.

appendices with borderline measurements, and 1 with minimal histologic findings at pathology.

Of the 13 false-positive studies, all had sonographic McBurney’s point tenderness, and 7 had periappendiceal inflammation. One patient had an appendiceal wall hematoma as a result of von Willebrand’s disease.²⁴ There was a single false positive among studies conducted after 50 scans’ experience, an appendix called inflamed according to size (7.3 mm) and without periappendiceal inflammation. The CT reading was “probable early appendicitis.”

Sonographic test characteristics stratified by the clinician-indicated pretest probability of appendicitis are shown in Table E3, available online at <http://www.annemergmed.com>.

There was general agreement between pediatric emergency medicine and radiology measurements when concurrent studies were performed (Figure 4). In 3 of the 5 studies plotted outside the 95% CI range, both pediatric emergency medicine and radiology called the study result positive. In the remaining 2, pediatric emergency medicine ultrasonography correctly identified the positive and negative case of appendicitis. Of the 14 studies in which radiology and bedside measurements disagreed on the 6-mm discriminatory threshold, the diagnostic impression was correct in both in 4,

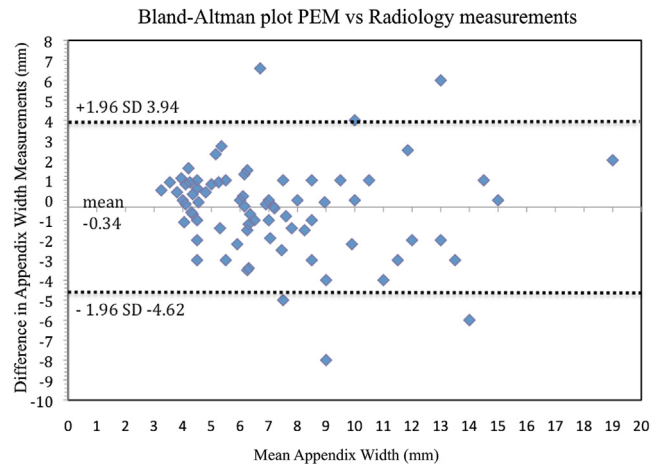


Figure 4. Bland-Altman plot of pediatric emergency medicine ultrasonography and radiology ultrasonographic measurements. The difference between pediatric emergency medicine and radiology measured appendix width (millimeters) is plotted against the mean pediatric emergency medicine and radiology measured appendix width. The horizontal line represents the mean difference for the group (–0.34 mm); and the dotted lines, the SD (3.94 to –4.62). There were 99 studies with pediatric emergency medicine and radiology measurements for comparison.

pediatric emergency medicine sonography was correct in 6, and radiology was correct in 4 (Table E4, available online at <http://www.annemergmed.com>).

In our blinded review of 189 images, the κ for appendix visualization was 0.69 (95% CI, 0.58 to 0.78). Raw agreement was 0.82 (95% CI, 0.77 to 0.87). In the 34 cases in which 2 pediatric emergency medicine examinations were independently performed on the same patient, the κ was 0.5 (95% CI, 0.2 to 0.82).

LIMITATIONS

Our study is limited by being from a single center in which pediatric emergency medicine fellows trained for this study may have acquired skills and training different from those elsewhere. Additionally, our lead sonographer performed 43% of the study imaging. We used a convenience sample based on sonographer availability.

We could not blind the sonographers to the patient’s pain during the examination, and this may have influenced their interpretations. We did not record the time required to complete the bedside sonographic examination, but our impression is that many positive scan results were quickly identified.

The children lost to follow-up may have presented elsewhere with appendicitis; however, our institution is the local referral center and they would likely been transferred for operative services. Furthermore, the frequency of missed appendicitis in recent studies (regardless of imaging strategy) is less than 0.5%²⁵⁻²⁷ and, even assuming a 10-fold higher frequency (5%) in patients lost to follow-up, would result in similar main results: sensitivity 84% (95% CI, 73% to 94%) and specificity 94% (95% CI, 86% to 100%).

DISCUSSION

In this prospective evaluation of focused right lower quadrant sonography by pediatric emergency physicians, we found substantial accuracy in the diagnosis of acute appendicitis.

In 1986, Puylaert¹⁷ described the technique of graded compression ultrasonography for the evaluation of acute appendicitis, which can be used to supplement clinical examination and laboratory algorithms.^{26,28-30} The application of sonography by emergency physicians to other surgical conditions of the abdomen is well established.³¹⁻³⁴

Zielke et al³⁵ studied surgical resident sonography for appendicitis in 504 adults and children, and found a sensitivity of 83% and specificity of 97%. Chen et al¹⁴ studied emergency physician sonography in 147 patients and found a sensitivity of 96% and a specificity of 68%. In a similar study, Fox et al¹⁵ found a sensitivity of 65% and a specificity of 90% in 132 patients. None of the studies describe their scanning protocols or visualization frequencies, and training was variable. Our standardized protocol and preferential use of a high-frequency linear probe may explain our greater accuracy.

We also found that pediatric emergency medicine ultrasonography was conducted on average 2-and-a-half hours earlier than the radiology studies, excluding the additional time for radiologist interpretation.

Ultrasonography remains highly operator dependent, with frequencies of radiologist appendiceal visualization ranging from 22% to 98%.³⁶⁻³⁸ We visualized the appendix in 71% of studies. Because nonvisualization can occur both with and without appendicitis, we used the presence or absence of secondary signs to dichotomize studies into “positive” or “negative” categories. The appendix may not be visualized after rupture, replaced by extensive inflammation and abscess formation.^{18,22,25,39} Nonvisualization with an adequate graded compression examination in the absence of free fluid or inflammation is generally considered a negative study result.^{21,22,40-46} This is the approach described by all of the English-language studies cited within the meta-analysis by Doria et al⁹ comparing ultrasonography accuracy with CT in children. We observed 8 cases of appendicitis with nonvisualization of the appendix, including 5 in which the sonographers had greater than 80% confidence in their falsely negative findings. This serves as a reminder that sonography, especially when not definitive, is imperfect and should not supersede overall clinical judgment.

We had 3 studies in which pediatric emergency medicine sonographers missed radiologist-identified appendicitis despite appendiceal visualization. In 2 of these cases, the sonographer measured a normal portion of the proximal appendix, overlooking distal disease. This stresses the importance of being able to trace an appendix to its blind end as we observed that frequently a normal-appearing proximal appendix could be seen before identification of the dilated and inflamed distal portion. Given that this dilated tip of the appendix is not always present in the right lower quadrant, a protocolized scanning strategy is recommended to avoid missing it.

We found greater accuracy when the appendix was visualized, consistent with a recent multicenter radiology study in which the sensitivity was 72.5% overall, but was 97.9% with clear visualization.⁴⁷

We found substantial agreement in appendiceal diameters between our sonographers and radiologists. There is some controversy about whether a better threshold might be 7 mm, and by measuring the thickness of the appendiceal outer wall.^{48,49}

Our finding of a positive likelihood ratio range of 7 to 20 based on 95% CIs suggests that when ED sonography result is positive, the diagnosis of appendicitis is essentially established and further studies do not appear to be required. Surgical consultants can be involved earlier in the ED course.

In summary, we found substantial diagnostic accuracy for pediatric emergency medicine sonography for acute appendicitis. Although the technique is imperfect, we believe that right lower quadrant sonography should be part of training in pediatric emergency medicine and emergency medicine ultrasonographic fellowships.

The authors acknowledge Kenneth Johnson, PhD, for his statistical support.

Supervising editor: Steven M. Green, MD

Author affiliations: From the Department of Emergency Medicine, Newark Beth Israel Medical Center, Children’s Hospital of New Jersey, Newark, NJ (Sivitz, Tejani); and the Department of Pediatric Emergency Medicine, Emory University, Children’s Healthcare of Atlanta, Atlanta, GA (Cohen).

Author contributions: ABS conceived and designed the study. All authors supervised the conduct of the trial and data collection and undertook recruitment of patients and managed the data, including quality control. ABS provided statistical advice on study design and analyzed the data. ABS drafted the article, and all authors contributed substantially to its revision. ABS takes responsibility for the paper as a whole.

Funding and support: By *Annals* policy, all authors are required to disclose any and all commercial, financial, and other relationships in any way related to the subject of this article as per ICMJE conflict of interest guidelines (see www.icmje.org). The authors have stated that no such relationships exist.

Publication dates: Received for publication June 28, 2013. Revisions received November 20, 2013; January 5, 2014; and March 13, 2014. Accepted for publication March 28, 2014. Available online May 23, 2014.

Presented at the American College of Emergency Physicians *Scientific Assembly*, October 2010, Las Vegas, NV.

REFERENCES

1. Bundy DG, Byerley JS, Liles EA, et al. Does this child have appendicitis? *JAMA*. 2007;298:438-451.
2. Lameris W, van Randen A, Go PM, et al. Single and combined diagnostic value of clinical features and laboratory tests in acute appendicitis. *Acad Emerg Med*. 2009;16:835-842.

3. Yen K, Karpas A, Pinkerton HJ, et al. Interexaminer reliability in physical examination of pediatric patients with abdominal pain. *Arch Pediatr Adolesc Med*. 2005;159:373-376.
4. Frei SP, Bond WF, Bazuro RK, et al. Appendicitis outcomes with increasing computed tomographic scanning. *Am J Emerg Med*. 2008;26:39-44.
5. Coursey CA, Nelson RC, Patel MB, et al. Making the diagnosis of acute appendicitis: do more preoperative CT scans mean fewer negative appendectomies? a 10-year study. *Radiology*. 2010;254:460-468.
6. Raja AS, Wright C, Sodickson AD, et al. Negative appendectomy rate in the era of CT: an 18-year perspective. *Radiology*. 2010;256:460-465.
7. Shah NB, Platt SL. ALARA: is there a cause for alarm? reducing radiation risks from computed tomography scanning in children. *Curr Opin Pediatr*. 2008;20:243-247.
8. Smith MP, Katz DS, Rosen MP, et al. ACR Appropriateness Criteria right lower quadrant pain—suspected appendicitis. Available at: <http://www.acr.org/~media/7425A3E08975451EAB571A316DB4CA1B.pdf>. Accessed August 30, 2013.
9. Doria AS, Moineddin R, Kellenberger CJ, et al. US or CT for diagnosis of appendicitis in children and adults? a meta-analysis. *Radiology*. 2006;241:83-94.
10. American College of Emergency Physicians. Emergency ultrasound guidelines. *Ann Emerg Med*. 2009;53:550-570.
11. Vieira RL, Hsu D, Nagler J, et al. Pediatric emergency medicine fellow training in ultrasound: consensus educational guidelines. *Acad Emerg Med*. 2013;20:300-306.
12. Riera A, Hsiao AL, Langhan ML, et al. Diagnosis of intussusception by physician novice sonographers in the emergency department. *Ann Emerg Med*. 2012;60:264-268.
13. Sivitz AB, Tejani C, Cohen SG. Evaluation of hypertrophic pyloric stenosis by pediatric emergency physician sonography. *Acad Emerg Med*. 2013;20:646-651.
14. Chen SC, Wang HP, Hsu HY, et al. Accuracy of ED sonography in the diagnosis of acute appendicitis. *Am J Emerg Med*. 2000;18:449-452.
15. Fox JC, Solley M, Anderson CL, et al. Prospective evaluation of emergency physician performed bedside ultrasound to detect acute appendicitis. *Eur J Emerg Med*. 2008;15:80-85.
16. Baldisserotto M, Marchiori E. Accuracy of noncompressive sonography of children with appendicitis according to the potential positions of the appendix. *AJR Am J Roentgenol*. 2000;175:1387-1392.
17. Puylaert JB. Acute appendicitis: US evaluation using graded compression. *Radiology*. 1986;158:355-360.
18. Sivit CJ. Diagnosis of acute appendicitis in children: spectrum of sonographic findings. *AJR Am J Roentgenol*. 1993;161:147-152.
19. Vasavada P. Ultrasound evaluation of acute abdominal emergencies in infants and children. *Radiol Clin North Am*. 2004;42:445-456.
20. Estey A, Poonai N, Lim R. Appendix not seen: the predictive value of secondary inflammatory sonographic signs. *Pediatr Emerg Care*. 2013;29:435-439.
21. Wiersma F, Toorenvliet BR, Bloem JL, et al. US examination of the appendix in children with suspected appendicitis: the additional value of secondary signs. *Eur Radiol*. 2009;19:455-461.
22. Sivit CJ, Applegate KE, Stallion A, et al. Imaging evaluation of suspected appendicitis in a pediatric population: effectiveness of sonography versus CT. *AJR Am J Roentgenol*. 2000;175:977-980.
23. Jones SR, Carley S, Harrison M. An introduction to power and sample size estimation. *Emerg Med J*. 2003;20:453-458.
24. Tejani C, Phatak T, Sivitz A. Right lower-quadrant pain—more than one diagnosis. *Pediatr Emerg Care*. 2012;28:1224-1226.
25. Douglas CD, Macpherson NE, Davidson PM, et al. Randomised controlled trial of ultrasonography in diagnosis of acute appendicitis, incorporating the Alvarado score. *BMJ*. 2000;321:919-922.
26. Kharbanda AB, Taylor GA, Fishman SJ, et al. A clinical decision rule to identify children at low risk for appendicitis. *Pediatrics*. 2005;116:709-716.
27. Kaiser S, Finnbogason T, Jorulf HK, et al. Suspected appendicitis in children: diagnosis with contrast-enhanced versus nonenhanced helical CT. *Radiology*. 2004;231:427-433.
28. Alvarado A. A practical score for the early diagnosis of acute appendicitis. *Ann Emerg Med*. 1986;15:557-564.
29. Samuel M. Pediatric appendicitis score. *J Pediatr Surg*. 2002;37:877-881.
30. Garcia Pena BM, Cook EF, Mandl KD. Selective imaging strategies for the diagnosis of appendicitis in children. *Pediatrics*. 2004;113:24-28.
31. Melniker LA, Leibner E, McKenney MG, et al. Randomized controlled clinical trial of point-of-care, limited ultrasonography for trauma in the emergency department: the first Sonography Outcomes Assessment Program trial. *Ann Emerg Med*. 2006;48:227-235.
32. Tayal VS, Graf CD, Gibbs MA. Prospective study of accuracy and outcome of emergency ultrasound for abdominal aortic aneurysm over two years. *Acad Emerg Med*. 2003;10:867-871.
33. Tayal VS, Cohen H, Norton HJ. Outcome of patients with an indeterminate emergency department first-trimester pelvic ultrasound to rule out ectopic pregnancy. *Acad Emerg Med*. 2004;11:912-917.
34. Summers SM, Scruggs W, Menchine MD, et al. A prospective evaluation of emergency department bedside ultrasonography for the detection of acute cholecystitis. *Ann Emerg Med*. 2010;56:114-122.
35. Zielke A, Hasse C, Sitter H, et al. "Surgical" ultrasound in suspected acute appendicitis. *Surg Endosc*. 1997;11:362-365.
36. Jo YH, Kim K, Rhee JE, et al. The accuracy of emergency medicine and surgical residents in the diagnosis of acute appendicitis. *Am J Emerg Med*. 2010;28:766-770.
37. Taylor GA. Suspected appendicitis in children: in search of the single best diagnostic test. *Radiology*. 2004;231:293-295.
38. Garcia Pena BM, Mandl KD, Kraus SJ, et al. Ultrasonography and limited computed tomography in the diagnosis and management of appendicitis in children. *JAMA*. 1999;282:1041-1046.
39. Borushok KF, Jeffrey RB Jr, Laing FC, et al. Sonographic diagnosis of perforation in patients with acute appendicitis. *AJR Am J Roentgenol*. 1990;154:275-278.
40. Ang A, Chong NK, Daneman A. Pediatric appendicitis in "real-time": the value of sonography in diagnosis and treatment. *Pediatr Emerg Care*. 2001;17:334-340.
41. Linam LE, Munden M. Sonography as the first line of evaluation in children with suspected acute appendicitis. *J Ultrasound Med*. 2012;31:1153-1157.
42. Trout AT, Sanchez R, Ladino-Torres MF, et al. A critical evaluation of US for the diagnosis of pediatric acute appendicitis in a real-life setting: how can we improve the diagnostic value of sonography? *Pediatr Radiol*. 2012;42:813-823.
43. Jaremko JL, Crockett A, Rucker D, et al. Incidence and significance of inconclusive results in ultrasound for appendicitis in children and teenagers. *Can Assoc Radiol J*. 2011;62:197-202.
44. Pacharn P, Ying J, Linam LE, et al. Sonography in the evaluation of acute appendicitis: are negative sonographic findings good enough? *J Ultrasound Med*. 2010;29:1749-1755.
45. Toprak H, Kilincaslan H, Ahmad IC, et al. Integration of ultrasound findings with Alvarado score in children with suspected appendicitis. *Pediatr Int*. 2014;56:95-99.
46. Sivit CJ, Newman KD, Boenning DA, et al. Appendicitis: usefulness of US in diagnosis in a pediatric population. *Radiology*. 1992;185:549-552.
47. Mittal MK, Dayan PS, Macias CG, et al. Performance of ultrasound in the diagnosis of appendicitis in children in a multicenter cohort. *Acad Emerg Med*. 2013;20:697-702.
48. Goldin AB, Khanna P, Thapa M, et al. Revised ultrasound criteria for appendicitis in children improve diagnostic accuracy. *Pediatr Radiol*. 2011;41:993-999.
49. Prendergast PM, Poonai N, Lynch T, et al. Acute appendicitis: investigating an optimal outer appendiceal diameter cut-point in a pediatric population. *J Emerg Med*. 2014;46:157-164.

Table E1. Test characteristics by quartile of sonographer VAS confidence.

Test Characteristics	Sonographer's VAS Confidence 0–66 (N=66)	VAS 67–84 (58)	VAS 85–94 (66)	VAS 94–100 (74)
Sensitivity (95% CI)	0.62 (0.34–0.88)	0.54 (0.24–0.85)	0.91 (0.78–1)	0.97 (0.88–1)
Specificity (95% CI)	0.94 (0.85–1)	0.91 (0.81–1)	0.95 (0.86–1)	0.89 (0.76–1)
PPV (95% CI)	0.73 (0.45–0.99)	0.6 (0.29–0.91)	0.91 (0.78–1)	0.9 (0.78–1)
NPV (95% CI)	0.91 (0.81–1)	0.9 (0.78–1)	0.95 (0.86–1)	0.97 (0.88–1)
LR+ (95% CI)	10.9 (3.3–35)	6.4 (2.2–19)	20 (5–76)	8.8 (3.5–22)
LR- (95% CI)	0.41 (0.2–0.81)	0.5 (0.26–0.96)	0.09 (0.02–0.34)	0.02 (0.004–0.2)

PPV, Positive predictive value; NPV, negative predictive value; LR+, positive likelihood ratio; LR-, negative likelihood ratio.

Table E2. Test characteristics by sonographer visualization and experience.

Test Characteristics	Studies Conducted by All (N=264)	Studies With Appendix Visualized (N=189)	Sonographers With >25 Scans (133)	Sonographers With <25 Scans (131)
Sensitivity (95% CI)	0.85 (0.74–0.95)	0.95 (0.86–1)	0.88 (0.76–1)	0.82 (0.69–0.95)
Specificity (95% CI)	0.93 (0.85–1)	0.88 (0.8–0.97)	0.98 (0.9–1)	0.87 (0.78–0.97)
LR+ (95% CI)	11.7 (6.9–20)	8.2 (4.9–13.8)	40 (10–160)	6.5 (3.7–11.5)
LR- (95% CI)	0.16 (0.1–0.27)	0.06 (0.02–0.15)	0.12 (0.05–0.28)	0.2 (0.11–0.39)

Table E3. Test characteristics by decile for treating physician's pretest probability for acute appendicitis, determined by VAS (0 to 100 mm).

Test Characteristics	Clinical VAS									
	0 to 10	11 to 20	21 to 30	31 to 40	41 to 50	51 to 60	61 to 70	71 to 80	81 to 90	91 to 100
Sensitivity (95% CI)	—	1 (0.05 to 1)	1 (0.01 to 1)	1 (0.3 to 1)	0.6 (0.17 to 1)	0.83 (0.53 to 1)	0.88 (0.68 to 1)	0.81 (0.62 to 1)	0.91 (0.76 to 1)	0.87 (0.73 to 1)
Specificity (95% CI)	1 (0.68 to 1)	1 (0.79 to 1)	0.96 (0.89 to 1)	1 (0.81 to 1)	0.89 (0.75 to 1)	1 (0.65 to 1)	0.92 (0.78 to 1)	1 (0.72 to 1)	0.72 (0.46 to 0.99)	1 (0.56 to 1)
PPV (95% CI)	—	1 (0.05 to 1)	0.5 (-0.2 to 1.2)	1 (0.31 to 1)	0.5 (0.1 to 0.9)	1 (0.46 to 1)	0.89 (0.68 to 1)	1 (0.72 to 1)	0.78 (0.57 to 1)	1 (0.8 to 1)
NPV (95% CI)	1 (0.68 to 1)	1 (0.79 to 1)	1 (0.83 to 1)	1 (0.81 to 1)	0.92 (0.81 to 1)	0.91 (0.74 to 1)	0.92 (0.78 to 1)	0.81 (0.62 to 1)	0.88 (0.68 to 1)	0.7 (0.4 to 0.98)
LR+ (95% CI)	—	Inf	25 (3.8 to 170)	Inf	5 (2.2 to 18)	Inf	11.6 (1.84 to 77)	Inf	3.4 (2.1 to 9)	Inf
LR- (95% CI)	0	0	0	0	0.45 (0.25 to 0.82)	0.17 (0.03 to 0.85)	0.12 (0.02 to 0.7)	0.19 (0.11 to 0.32)	0.11 (0.02 to 0.73)	0.13 (0.07 to 0.2)
+ Appendicitis, N (%)	0	1 (5)	1 (4)	3 (12)	5 (17)	6 (37.5)	9 (41)	16 (55)	12 (52)	23 (77)

PPV, Positive predictive value; NPV, negative predictive value.

Table E4. Patients for whom measurements between radiology and pediatric emergency medicine bracket 6 mm, with comments on patient outcome.

Patient No.	Radiology, Size, mm	PEM, Size, mm	Comments
14	4	6.9	PEM correct, +AP
26	8	6.9	PEM correct, -AP
34	7	4.8	PEM correct, -AP
80	8	4.5	Rad correct, +AP
94	6.9	5.7	Rad correct, +AP
173	7	5.5	Both said nl
179	8	4.6	Rad correct, +AP
181	5.5	7	Both said nl
185	7	6	PEM correct, -AP
198	13	5	Both said +
201	3.4	10	PEM correct, +AP
208	5.5	6.8	Both said nl
241	4	6.7	Rad correct, -AP
250	10	5	PEM correct, -AP

PEM, Pediatric emergency medicine; +AP, positive appendicitis result; -AP, negative appendicitis result; Rad, radiology; both, pediatric emergency medicine and radiology.

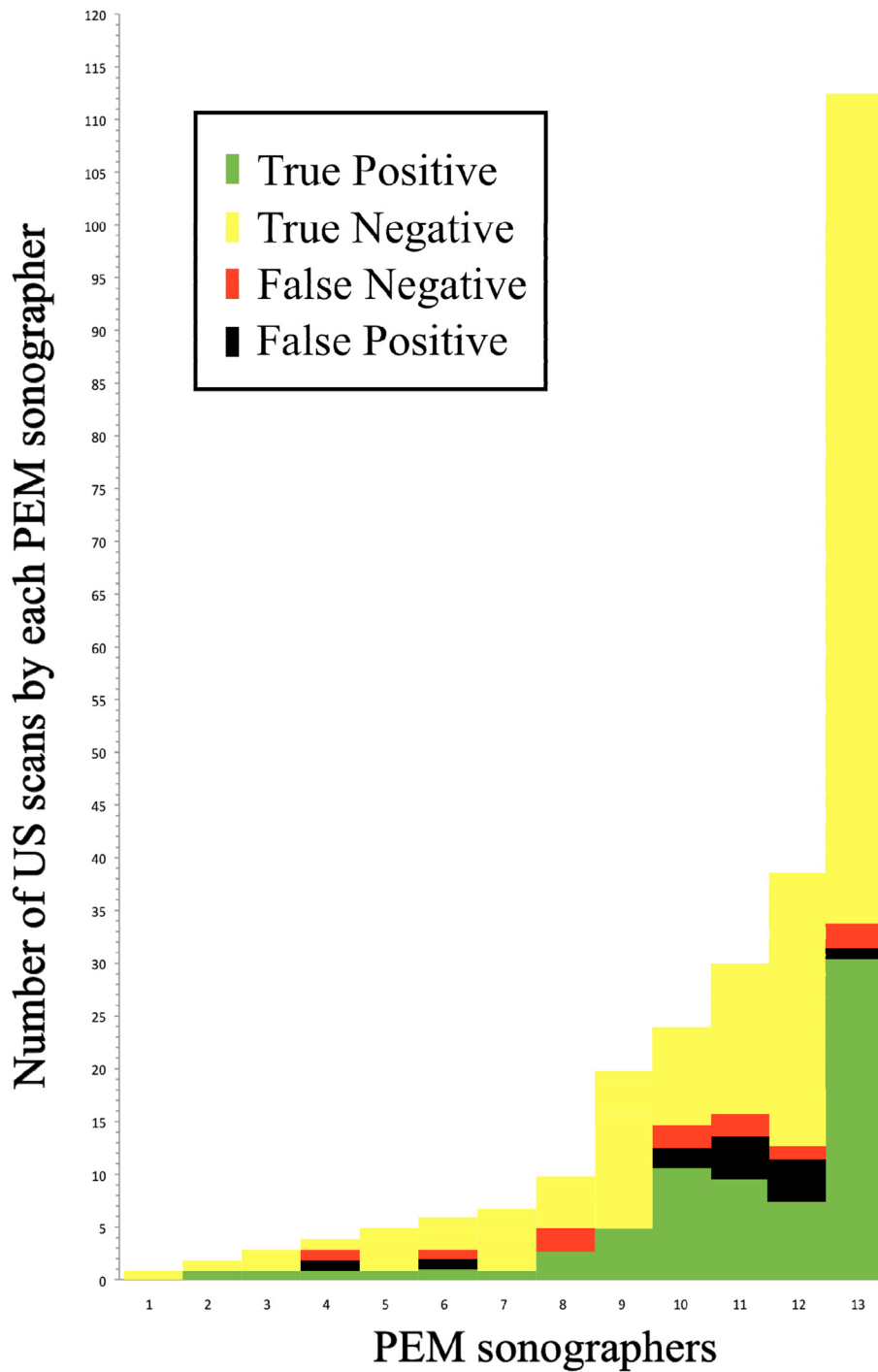


Figure E1. Diagnostic results for each pediatric emergency medicine sonographic study compared with the reference standard of surgical pathology or clinical follow-up. Each block represents a sonographic study performed by each pediatric emergency physician sonographer (x axis) and is color coded to show the test result.