

**AUSTRALASIAN COLLEGE FOR EMERGENCY MEDICINE
FELLOWSHIP EXAMINATION
5 AUGUST 2009 - PART C**

Question 7

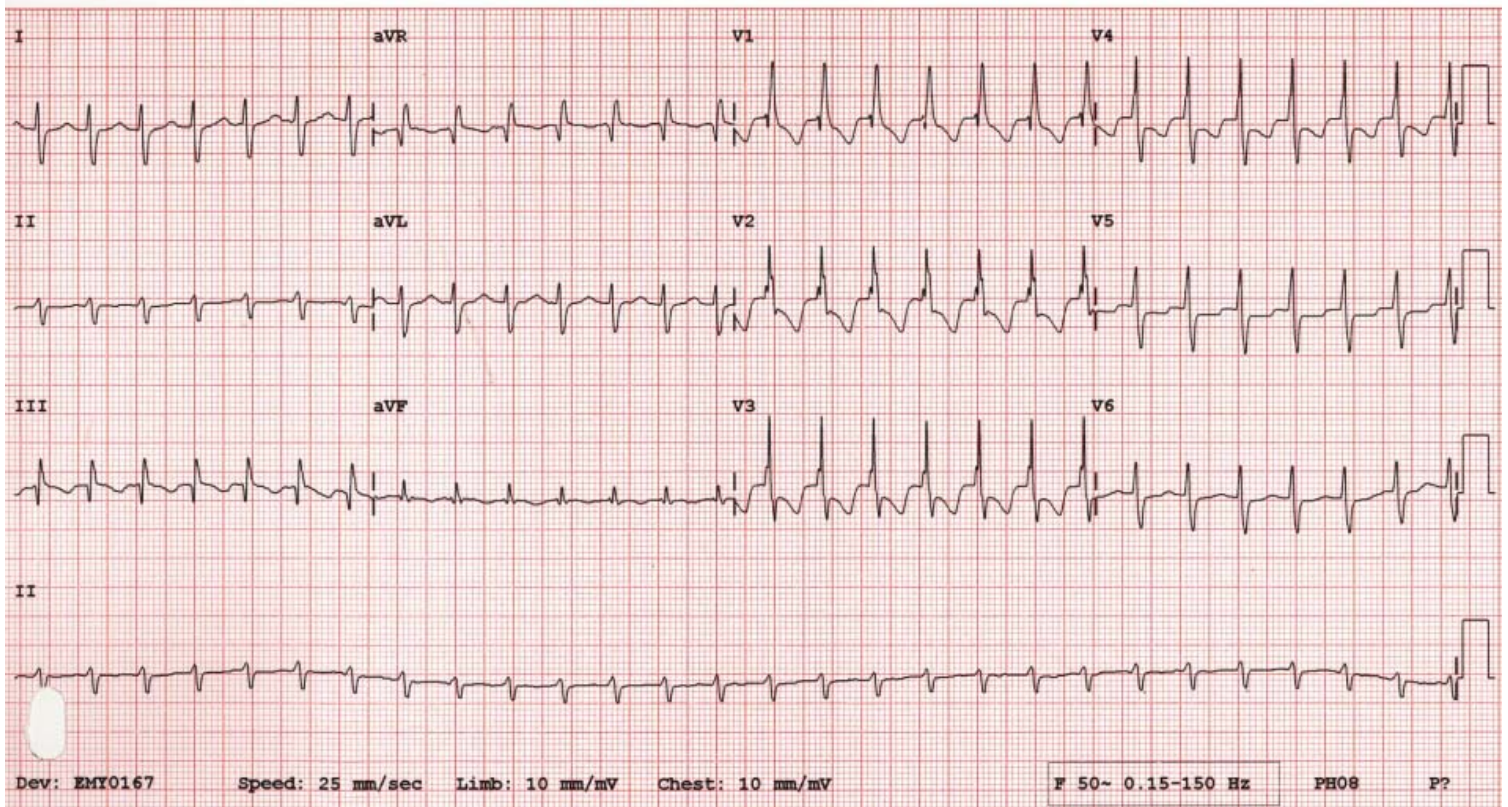
A 36 year old woman presents with palpitations for an hour. She is pain free and normotensive.

Describe and interpret her ECG

(100%)

**AUSTRALASIAN COLLEGE FOR EMERGENCY MEDICINE
FELLOWSHIP EXAMINATION
5 AUGUST 2009 - PART C**

Question 7 ECG



**AUSTRALASIAN COLLEGE FOR EMERGENCY MEDICINE
FELLOWSHIP EXAMINATION
5 AUGUST 2009 - PART C**

Question 8

A 70 year old woman presents with two days of increasing abdominal pain and vomiting.

- a. Describe and interpret her abdominal X-ray (50%)
- b. Outline your management (50%)

**AUSTRALASIAN COLLEGE FOR EMERGENCY MEDICINE
FELLOWSHIP EXAMINATION
5 AUGUST 2009 - PART C**

Question 8 X-ray

