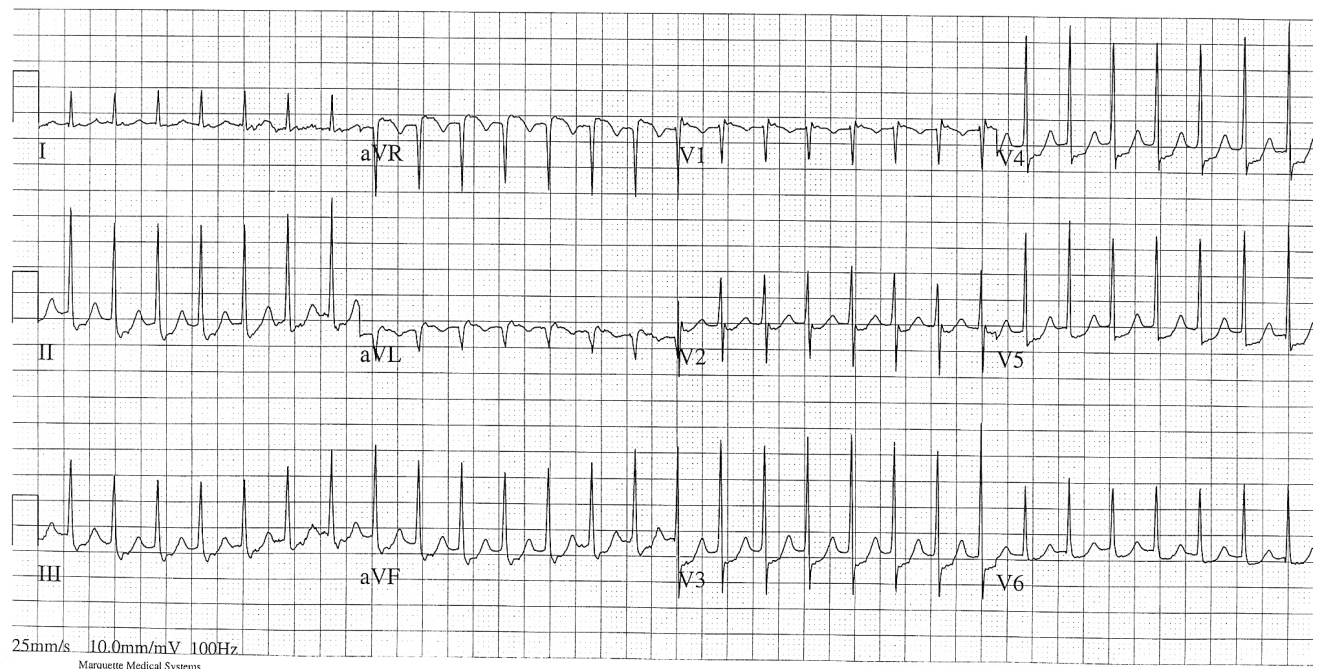


Tachyarrhythmia

Question 1

A 40-year-old woman presents to ED with palpitations. She has a history of recurrent SVT. She is awake and haemodynamically stable. She has no other medical problems and no allergies. Her ECG is attached (ECG 1)

1. What is your approach to this patient?
2. Discuss the use of Adenosine vs Verapamil in this patient



Question 2

A 65-year-old man present to the ED with palpitations, which he has never before. He has no chest pain. He is awake and oriented. He has a history of hyperlipidaemia and hypertension (but has left his medications at home).

His vital signs are: HR 130 irreg, BP 95/65, RR 18, O₂ sats 96% RA, afebrile.

His ECG is attached (ECG 2).

1. What is your approach to this patient?
2. Discuss the concept of 'Rhythm Control vs Rate Control'
3. When would you consider anticoagulation for this patient?

Despite treatment, the patient remains in AF, with a rate of 105

4. What factors will determine whether this patient is safe for Discharge?

