

Candidate name: \_\_\_\_\_

Department of  
Emergency Medicine

Princess Alexandra Hospital

**FELLOWSHIP TRIAL EXAMINATION**  
2017.2

**WRITTEN EXAMINATION**

**SHORT ANSWER QUESTIONS**

**PROPS**  
**BOOKLET**

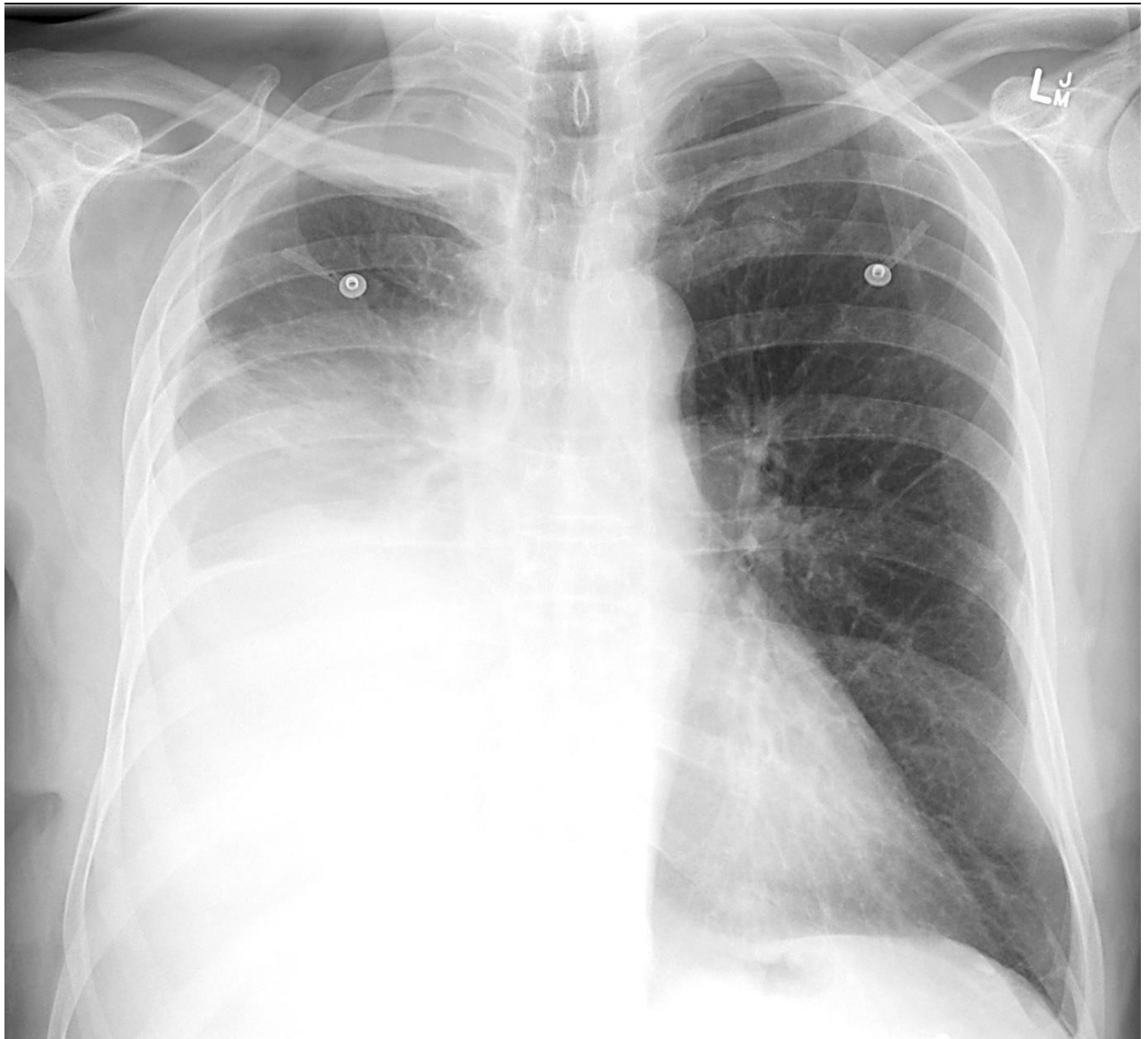
Candidate initials: \_\_\_\_\_

Candidate initials: \_\_\_\_\_

**Q1**

A 65 year old man has presented to hospital with shortness of breath.

A chest x-ray is provided below.



**Q4**

A 78 year old woman has presented to the ED after a 3 day history of lethargy. She has been febrile and has complained of dysuria and right flank pain.

Her past medical history includes type 2 diabetes mellitus, congestive cardiac failure and hypertension.

Her blood results are given below.

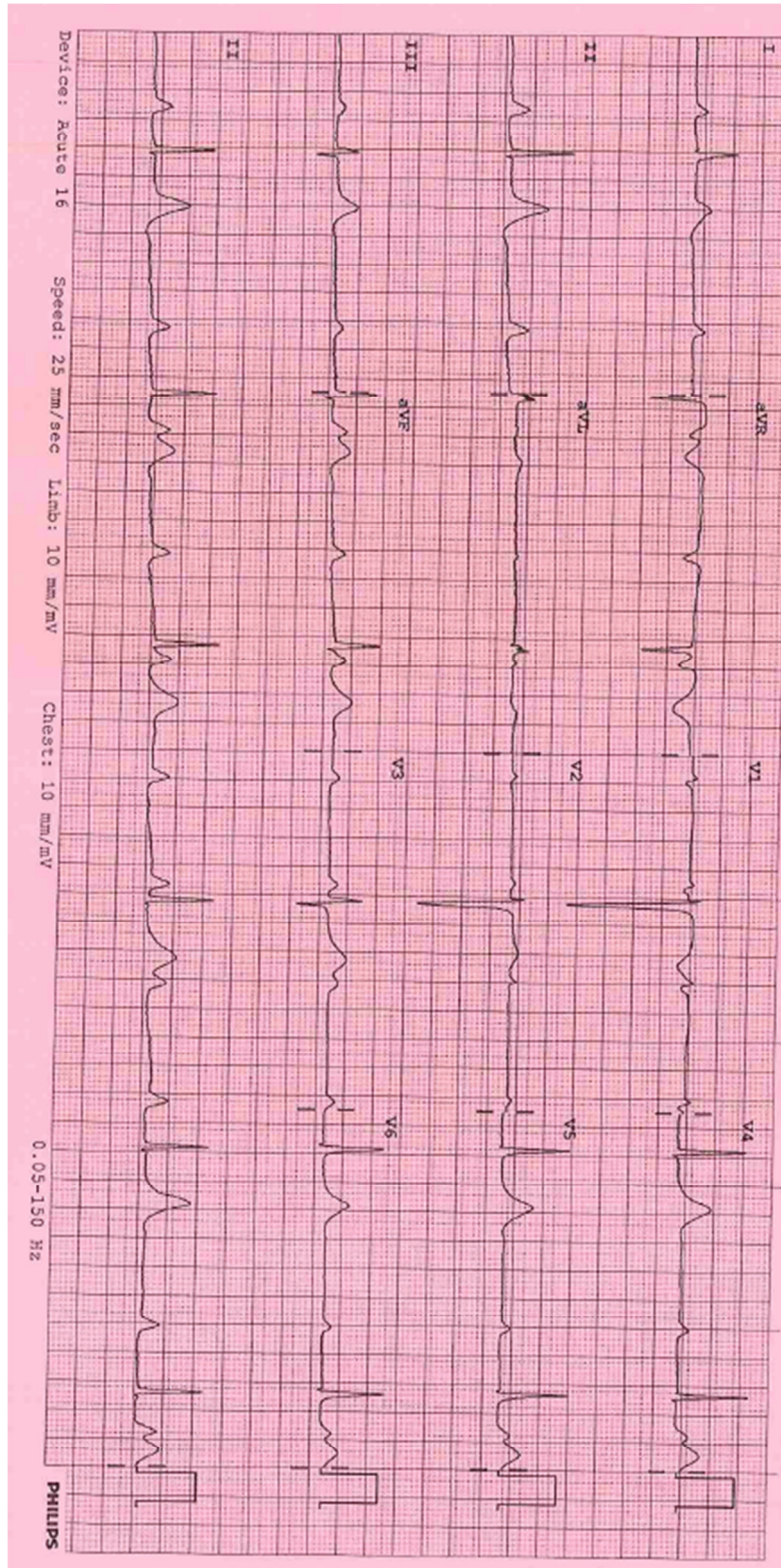
			Ref Range
Na	119	mmol/L	(135-145)
K	8.4	mmol/L	(3.5-4.5)
Cl	82	mmol/L	(100-110)
HCO <sub>3</sub>	6	mmol/L	(22-32)
Glucose	66.6	mmol/L	(3.0-7.8)
Urea	15.7	mmol/L	(3.1-7.1)
Creatinine	298	umol/L	(70-120)



**Q5**

A 72 year old man has been brought to the ED with dizziness.

His ECG is given below.

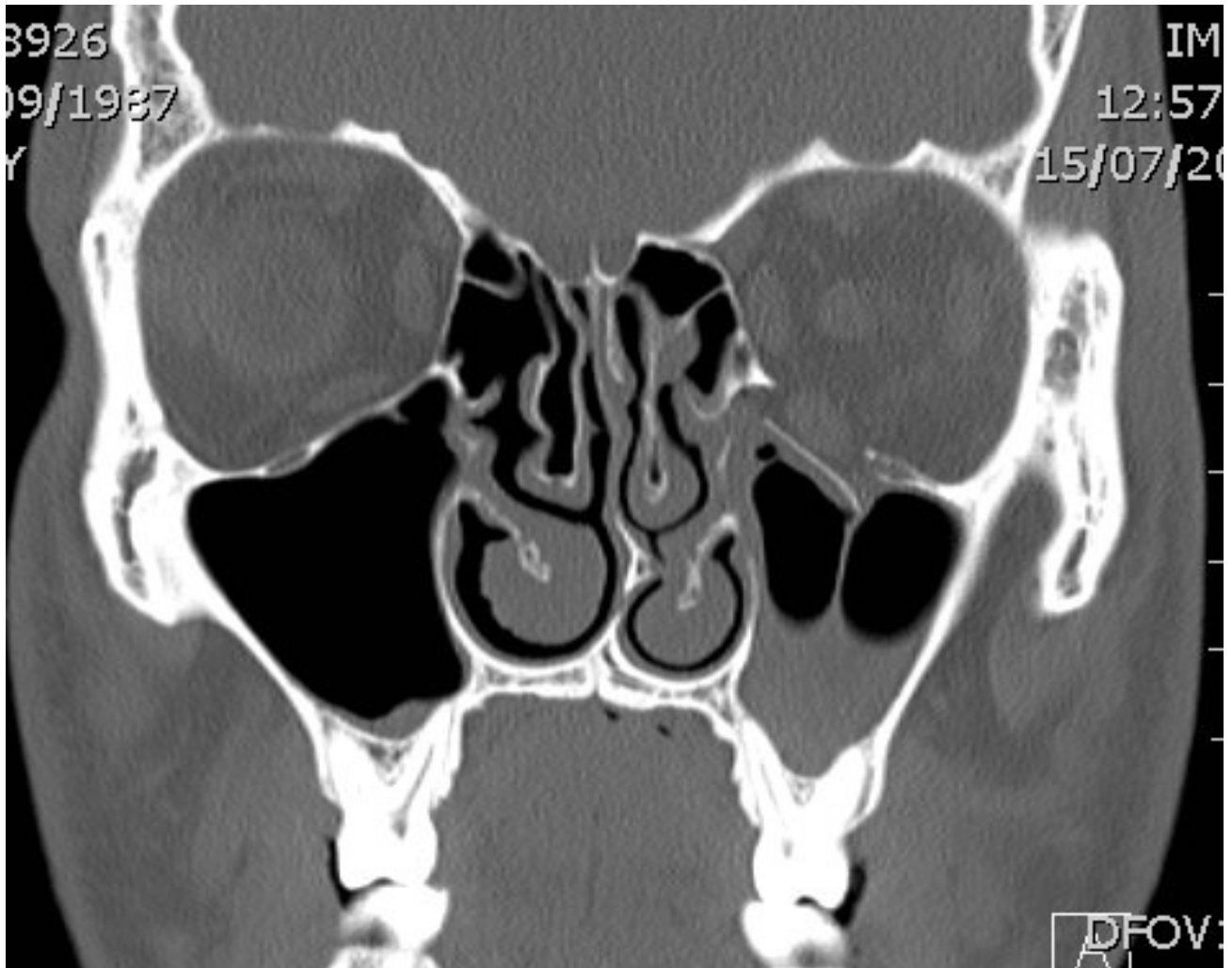


Candidate initials: \_\_\_\_\_

Q7

A 20 year old man has been punched to the face during an altercation at a bar. He is complaining of a painful, swollen face.

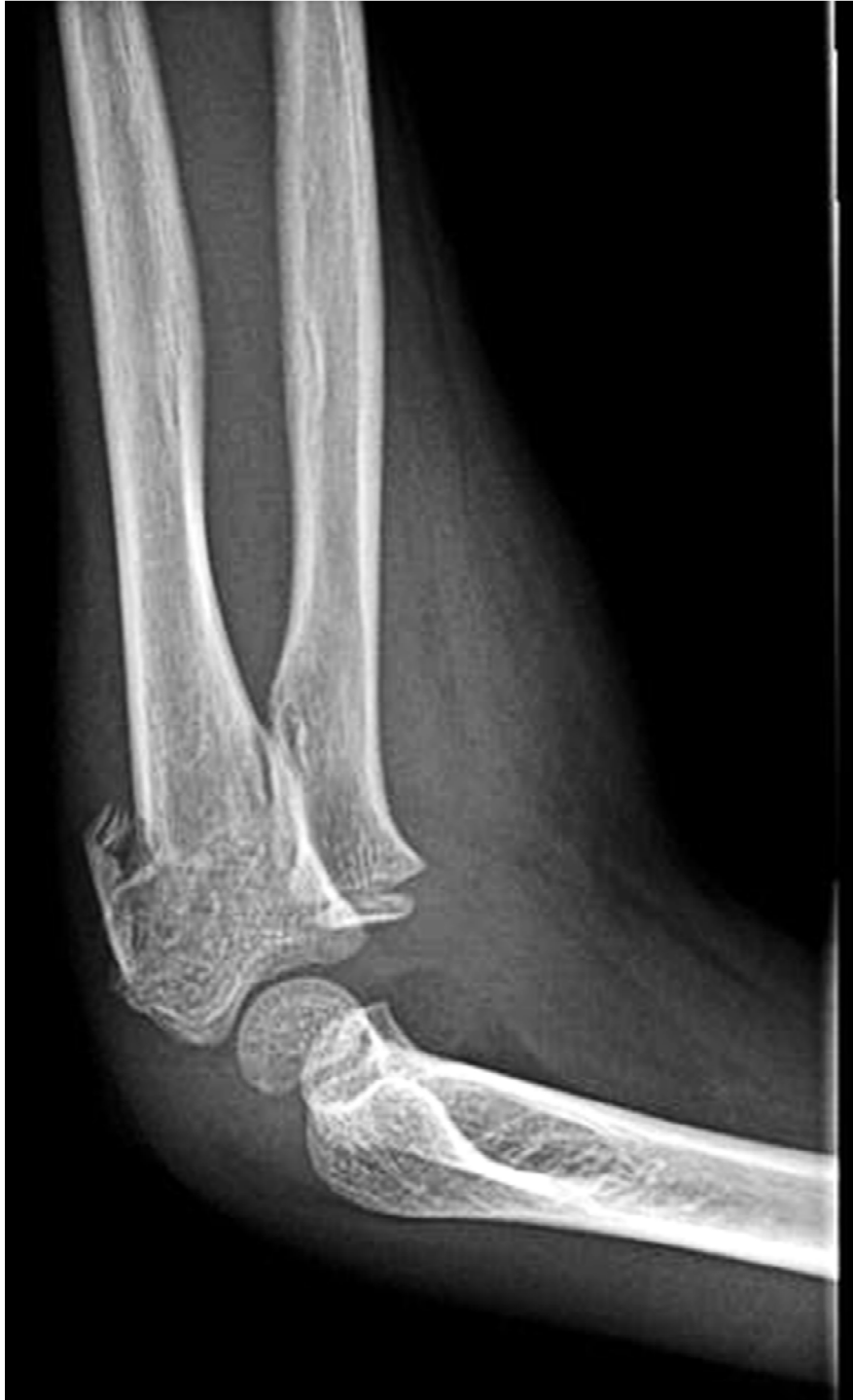A coronal slice from his CT scan is provided below.



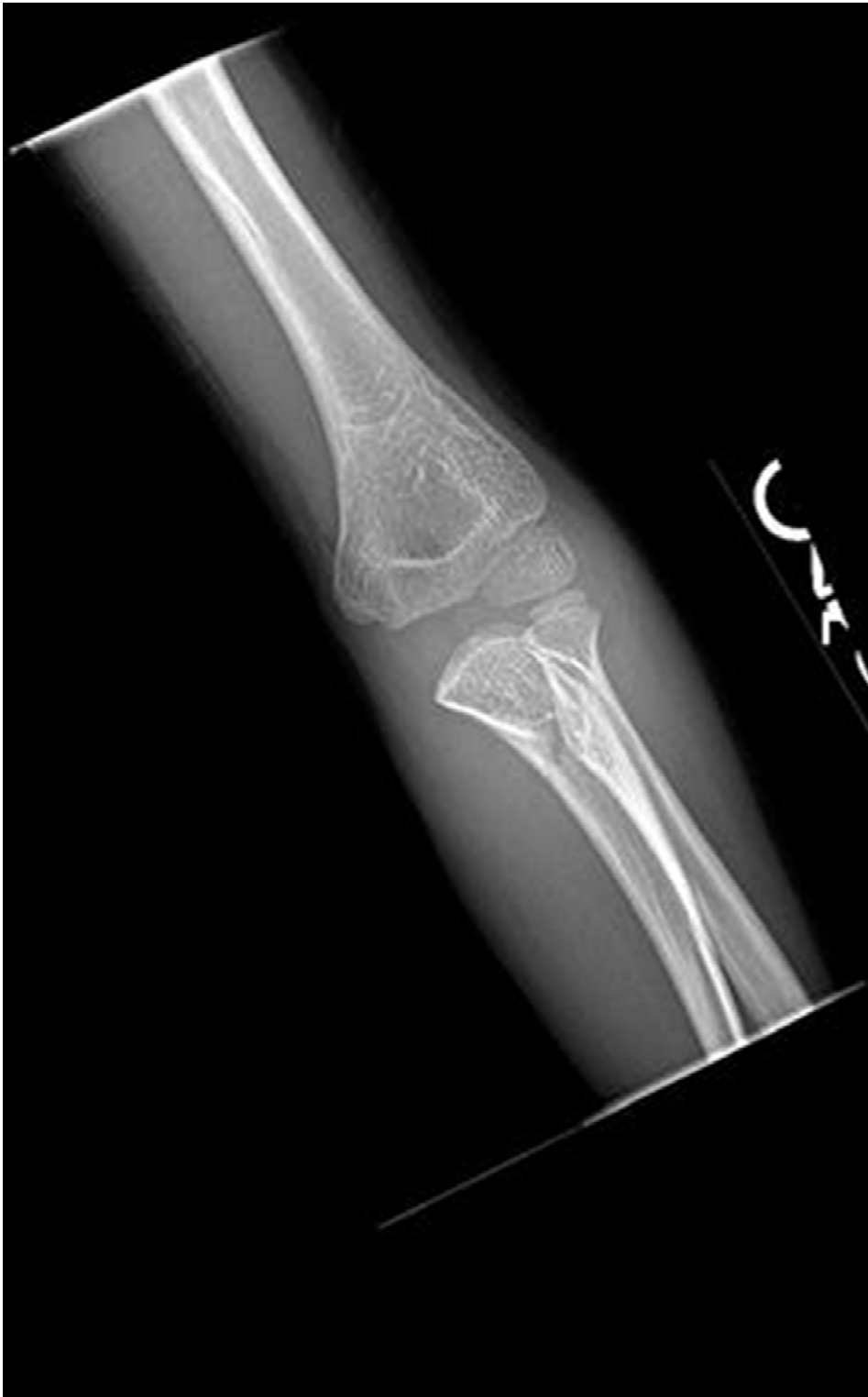**Q8**

A 7 year old boy has injured his left arm after falling off a swing in the playground.

His x-rays (lateral and AP) are provided on the following 2 pages.



Candidate initials: \_\_\_\_\_



**This paper is property of the Princess Alexandra Hospital Emergency Department and should not be distributed or published in any way without written permission**

Candidate initials: \_\_\_\_\_

**Q10 (12 min)**

A 50 year old farmer has been run over by a tractor.

He has severe pelvic pain.

His vital signs are:

GCS 13            E3 V4 M6

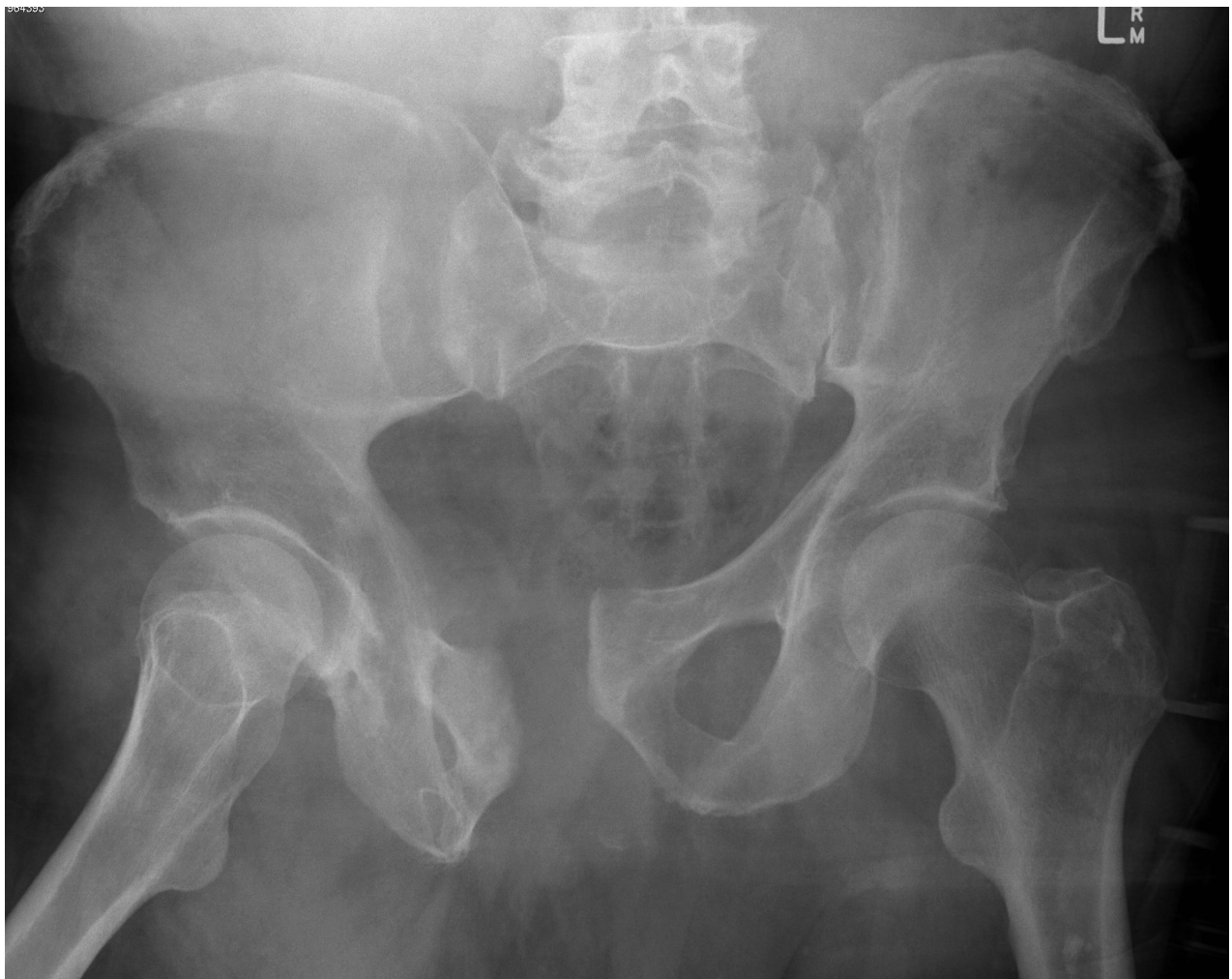Pulse            140                    /min

BP                70/30                mmHg

O2 Sats          99%                 room air

His CXR is normal.

His pelvic x-ray is given below.

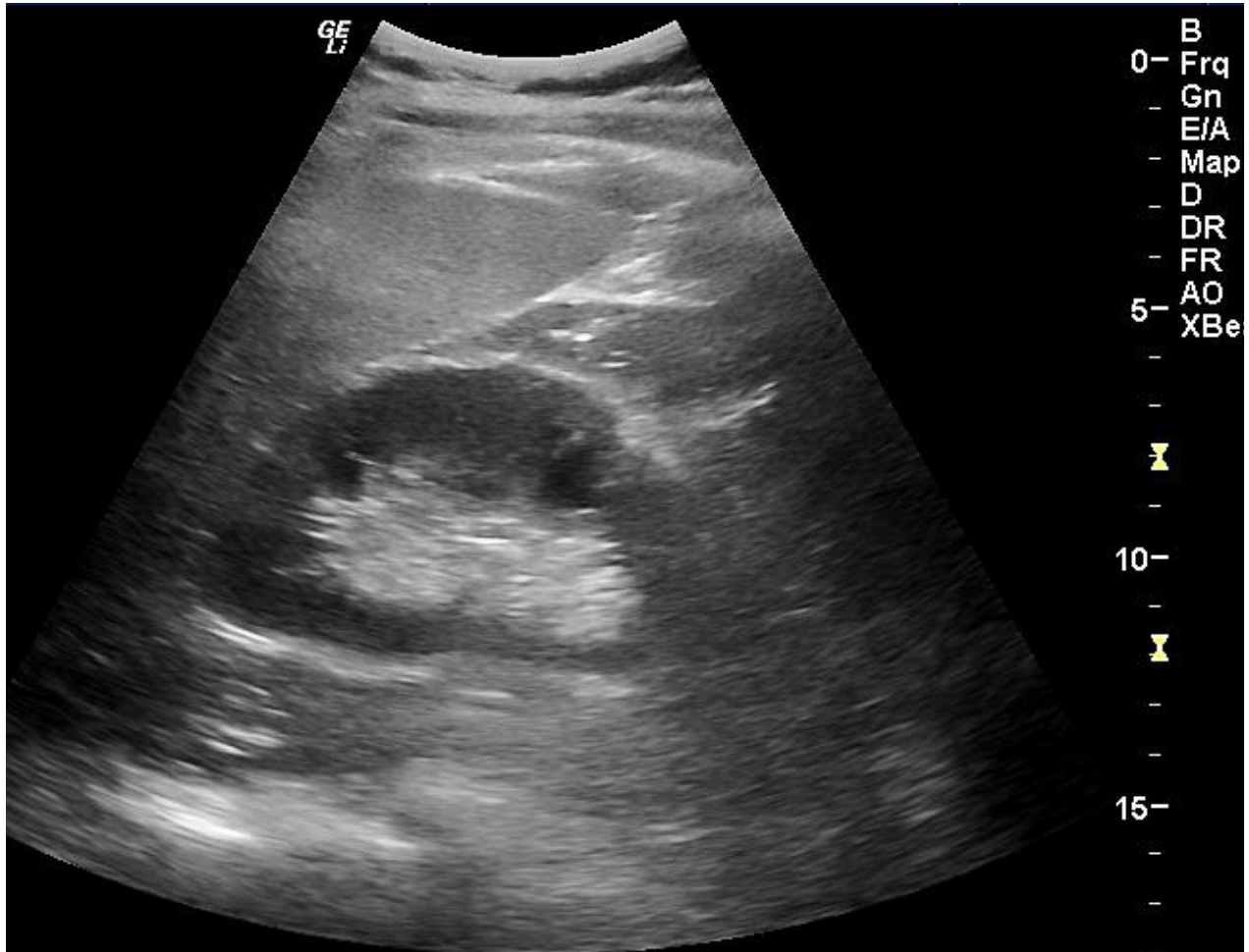



Candidate initials: \_\_\_\_\_

Q10 continued

As part of your assessment a FAST scan is performed. The image obtained is provided below.



**Q13**

A 5 week old baby has been brought to ED with vomiting and lethargy.

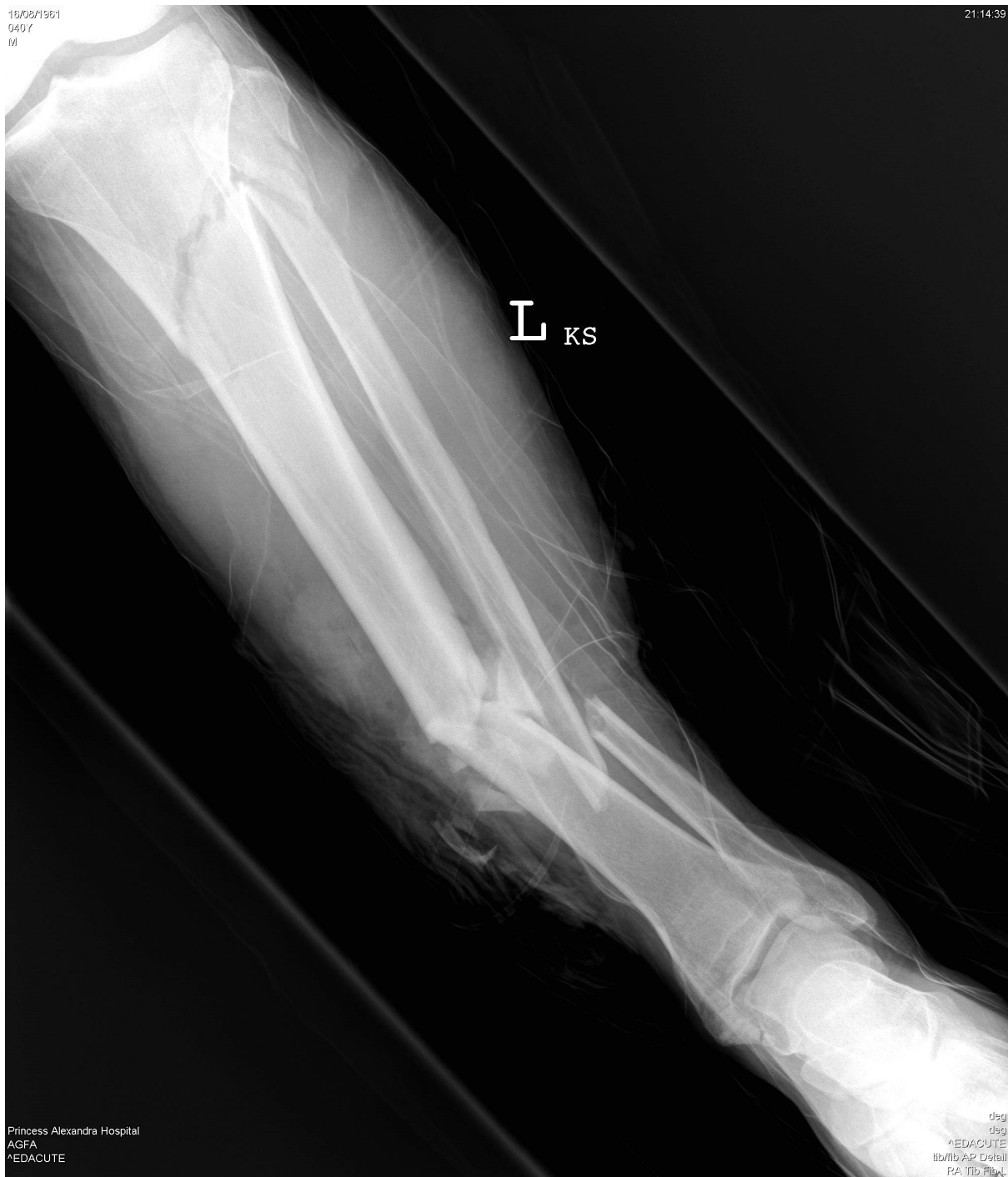A venous blood gas had been obtained. The result is provided below.

			Reference range
pH	7.60		(7.35-7.45)
pCO <sub>2</sub>	55	mmHg	(35 - 45)
pO <sub>2</sub>	44	mmHg	
HCO <sub>3</sub>	51	mmol/L	(20-28)
BE	14	mmol/L	(-3 - +3)
Na	138	mmol/L	(135-145)
K	4.0	mmol/L	(3.5-4.5)
Cl	69	mmol/L	(88-108)
Gluc	4.1	mmol/L	(3.0-5.5)
Lact	3.3	mmol/L	(<2.0)

**Q16**

You are called to see a patient in your department who is awaiting orthopaedic admission for a complex lower leg fracture requiring operative fixation. Your registrar has placed the patient in an above knee cast which has been split laterally. The nurses are worried that the patient has increasing pain and distress. The orthopaedic registrar has been repeatedly delayed due to theatre cases.

The initial xray (prior to immobilisation) is provided below.



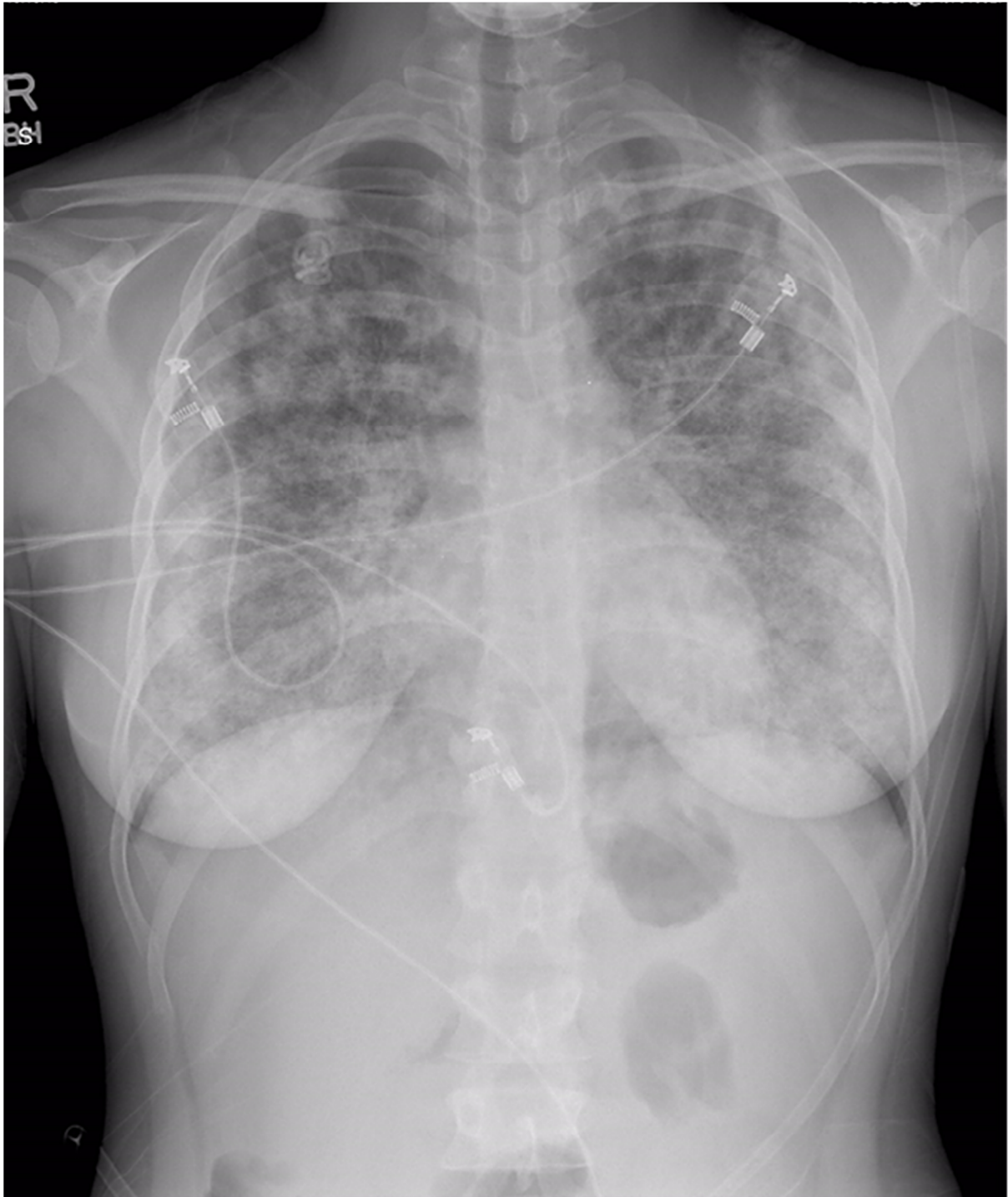


**Q18**

A 30 year old woman has been brought to the ED with dyspnoea.

She is receiving chemotherapy for treatment of melanoma.

Her chest x-ray is provided below.

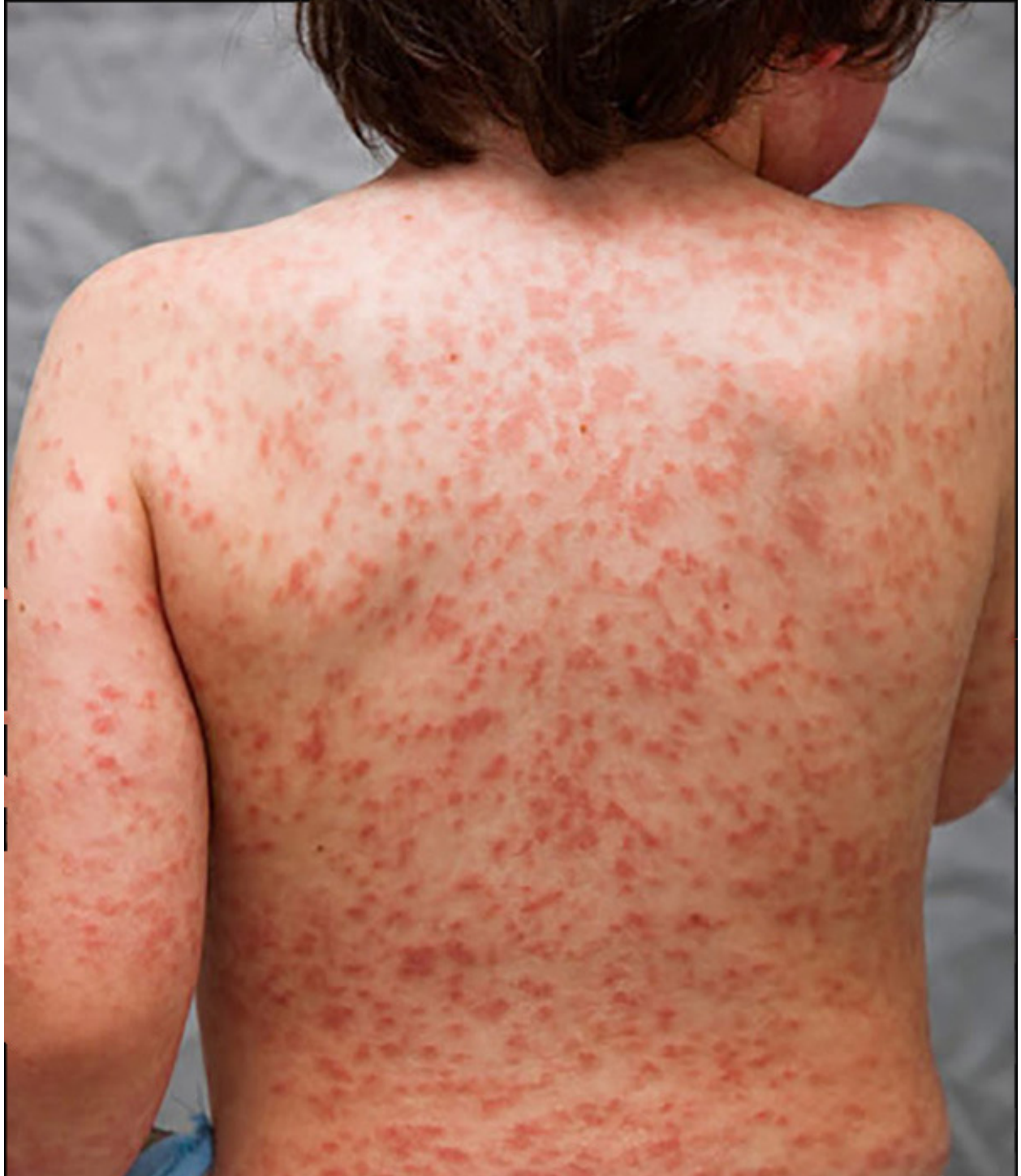

Candidate initials: \_\_\_\_\_

**Q19**

A 3 year old boy has presented with a rash. The junior medical officer who has seen the patient is concerned about the possibility of Kawasaki disease.

A photograph of the rash is provided below.



**Q20**

A 54 year old man has presented to the ED with epigastric abdominal pain and fevers for the last 24 hours.

Some of his blood results are provided below.

			Reference Range
Protein	88	g/L	(60 – 80)
Albumin	32	g/L	(35 – 50)
Globulin	55	g/L	(25 – 45)
Bilirubin	88	umol/L	(<20)
Bili (conj)	62	umol/L	(<4)
ALP	540	U/L	(30 – 110)
GGT	503	U/L	(<38)
ALT	190	U/L	(<34)
AST	181	U/L	(<31)
LDH	415	U/L	(120 – 250)
Lipase	120	U/L	(<70)

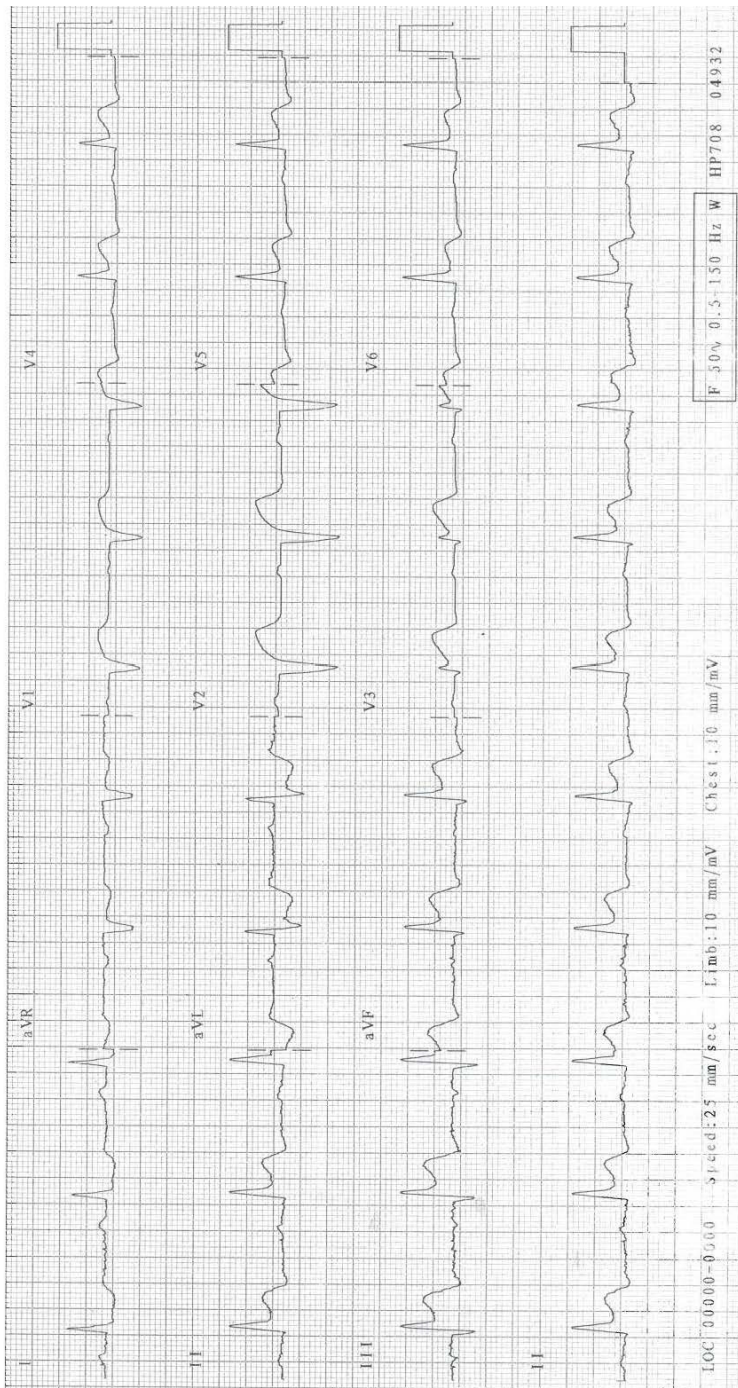
**Q22**

A 25 year old man has presented with severe central chest pain of 12 hours duration.

He has been unwell for one week with lethargy and malaise following an upper respiratory tract infection diagnosed by his GP.

He has no past medical history.

His ECG is provided below.





Candidate initials: \_\_\_\_\_

**Q25**

A seven year old girl has presented with a 48 hour history of a swollen right eye. There is no history of trauma.

Her clinical photograph is provided below.

