

Small Group Tutorial - Eye injuries

Q1

45 yo male presented to your ED after blunt injury to the eye.

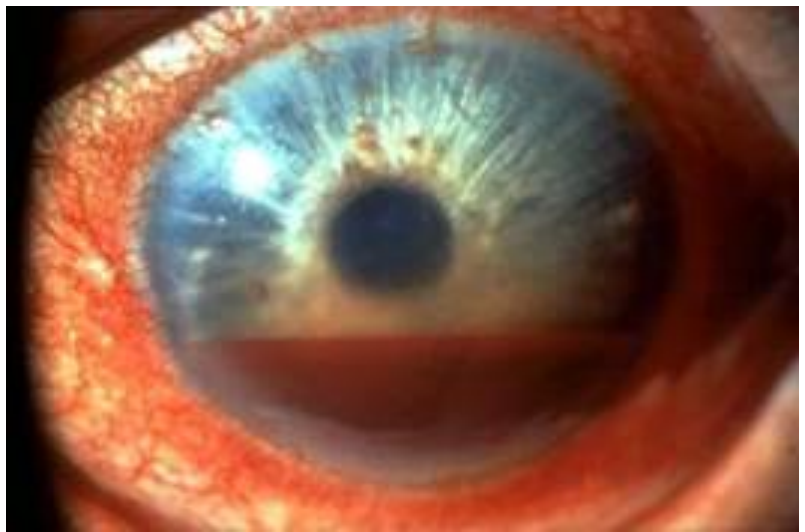Describe the photo.

What is the diagnosis?

How would you further assess the patient?

What is your management/ disposition?

What advice will you give to the patient on discharge?



Q2

35 yo female presented to your ED 1 day after L eye injury. She was playing cricket with friends (not wearing protective mask), when the ball hit her in the face.

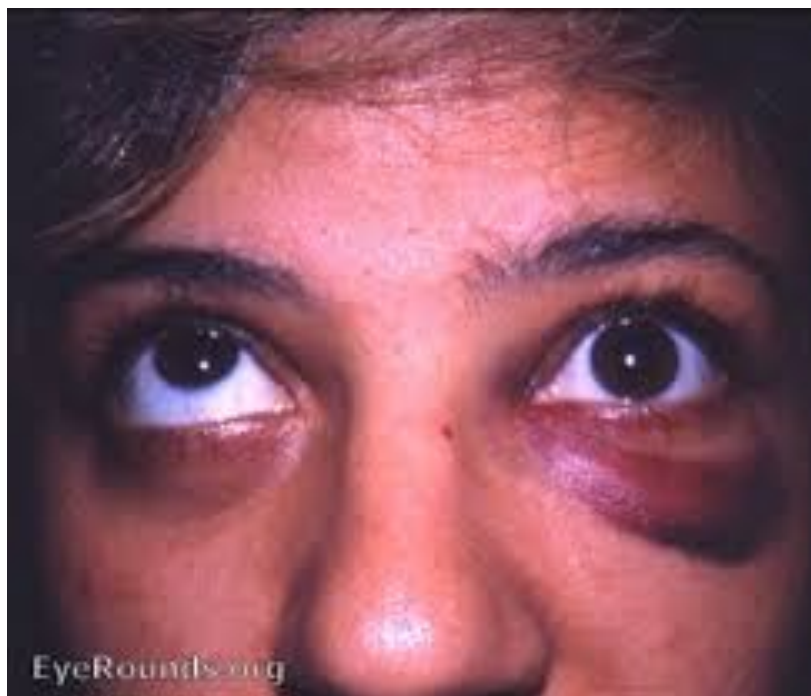She was asked to look up.

Please describe and interpret the photo.

How would you further assess this patient?

The CT of her facial bones was performed.

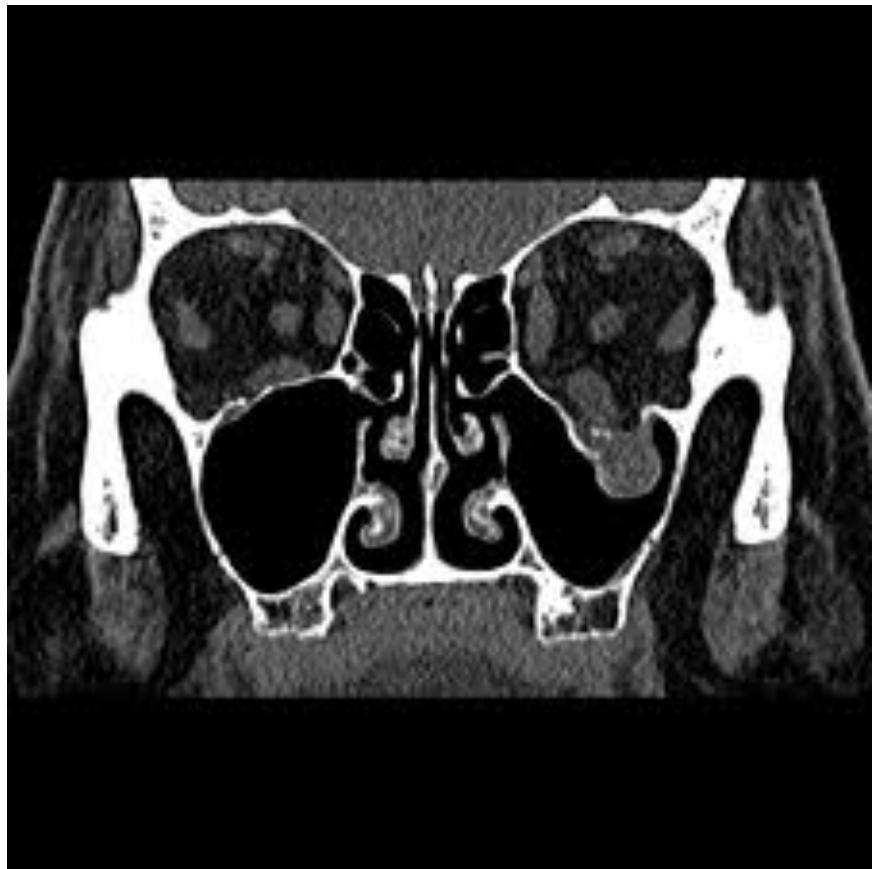Please describe the imaging on the next page.



What is diagnosis?

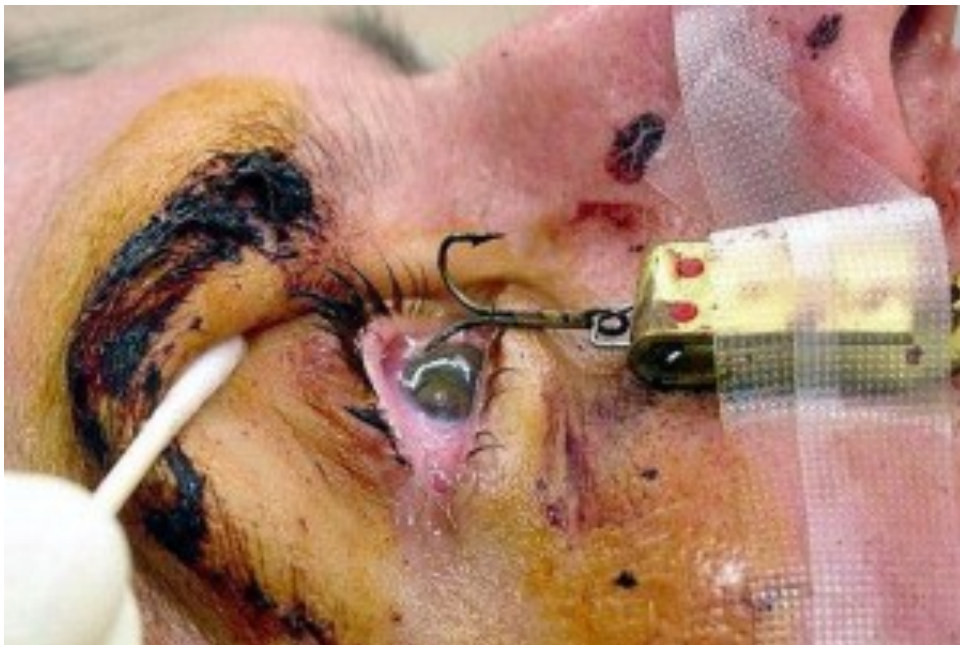What is your initial management?

Disposition?



Q3

You took some weekend locum shifts in the ED of a country hospital. You were expecting a quiet time, when a group of loud young “locals” brought their friend in from a fishing expedition. They were demanding prompt intervention asking you to remove the hook from their friend’s eye.



What is your response?

How would you deal with this situation?

Describe and interpret the photo.

What are the structures potentially affected in the eye?

What is your initial management?

What is your disposition?

As your hospital does not have ophthalmology service, you contacted referring hospital ophthalmology fellow who asked you to send the patient ASAP to him, as he has the plan to operate on your patient that afternoon.

Discuss the best mode of transport of this patient to the hospital. Hospital is 250 km away by the road, and all modes of transport are available to you.

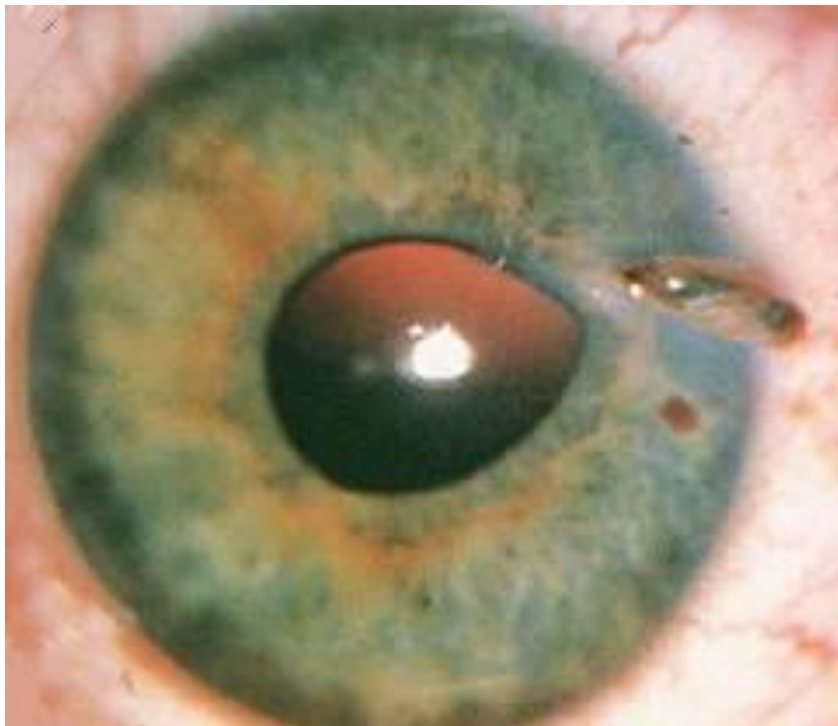Q4

This 18 yo mechanic apprentice, was hammering the piece of metal when he suddenly felt the pain in his eye. Initially severe pain became less so. He presented to your ED and your intern has seen him.

Your best intern examined the eye and he believed that he saw FB on 3 o'clock and is asking you for permission to remove it with needle as he has seen FB removal once.

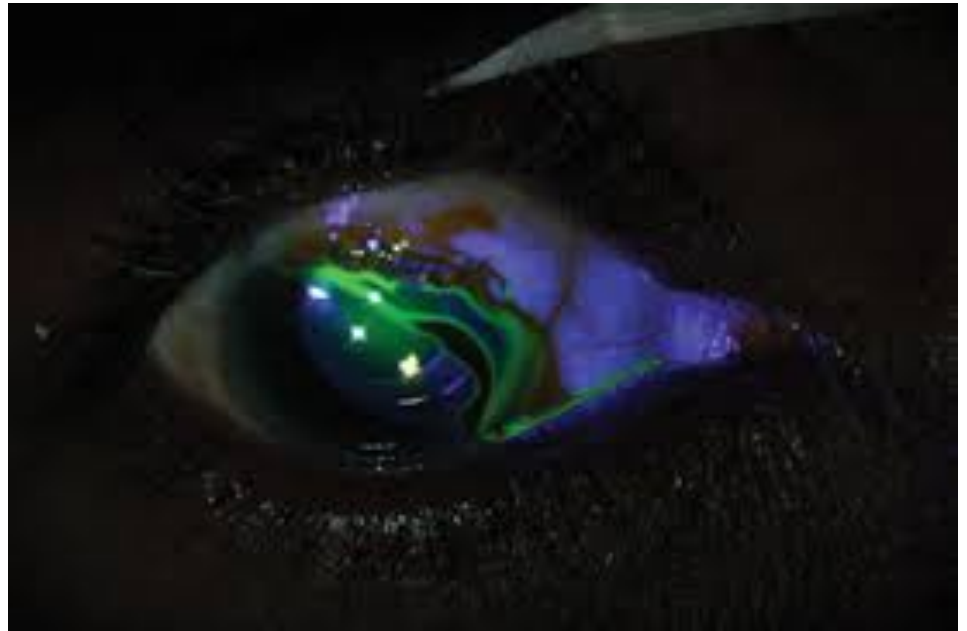
What would you tell to your intern???

What further assessment do you have to make?

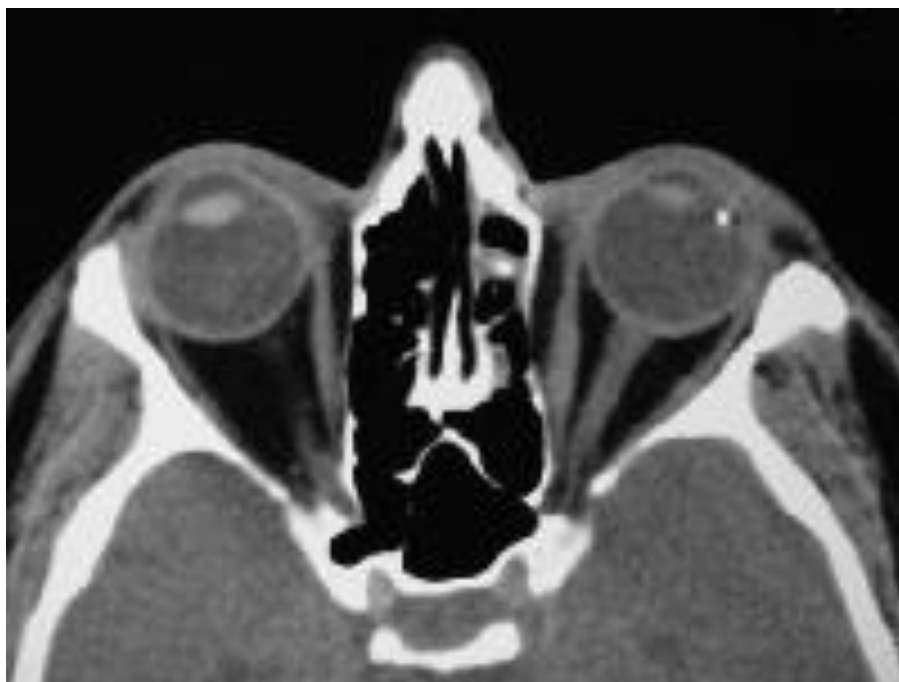

What is Siedel's test?

Describe how would you perform it?



Describe and interpret this CT. What is your management/disposition?

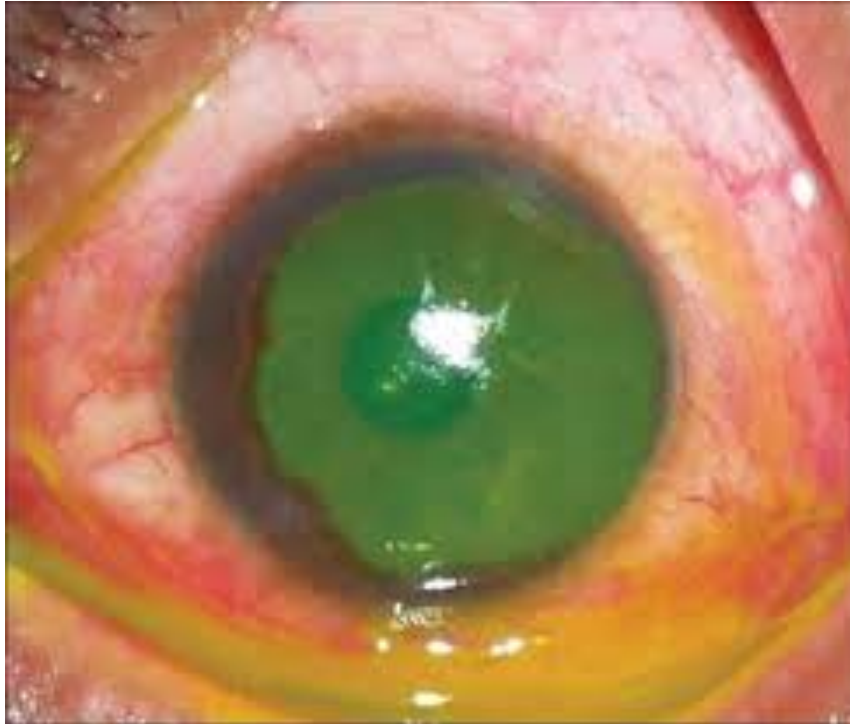

Q5

50 yo cleaner presented to your department after splashing some bleach to the eye. Initially washed the eye copiously but still has pain.

Describe your initial assessment/management.

After initial management you assessed the eye with slit lamp/using local anaesthetics and fluorescein.



Describe and interpret the photo.

What is your management/disposition of this patient?

What is this piece of equipment?

Do you know when and how to use it?

