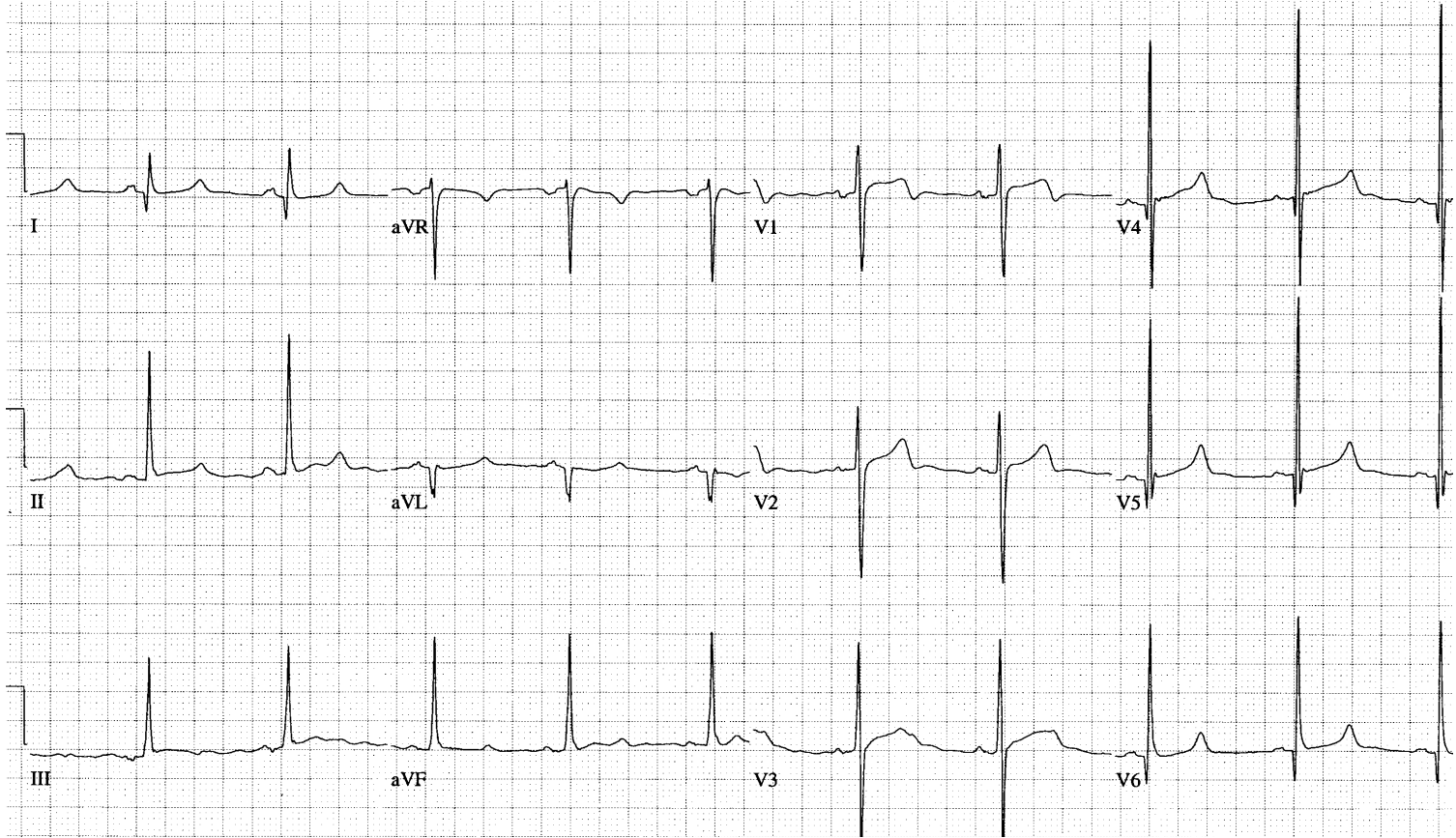
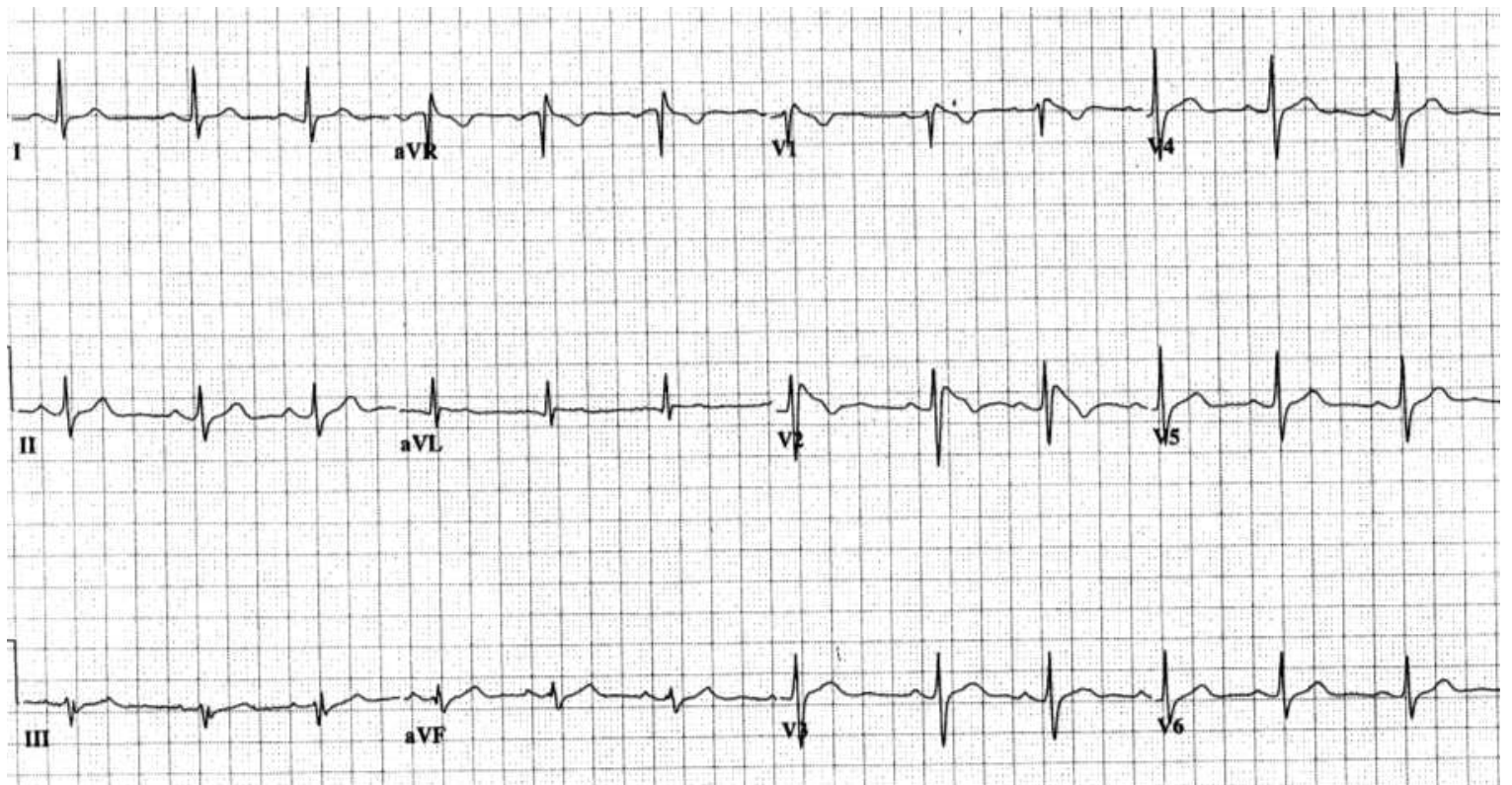


Small Group Tutorial – ECGs

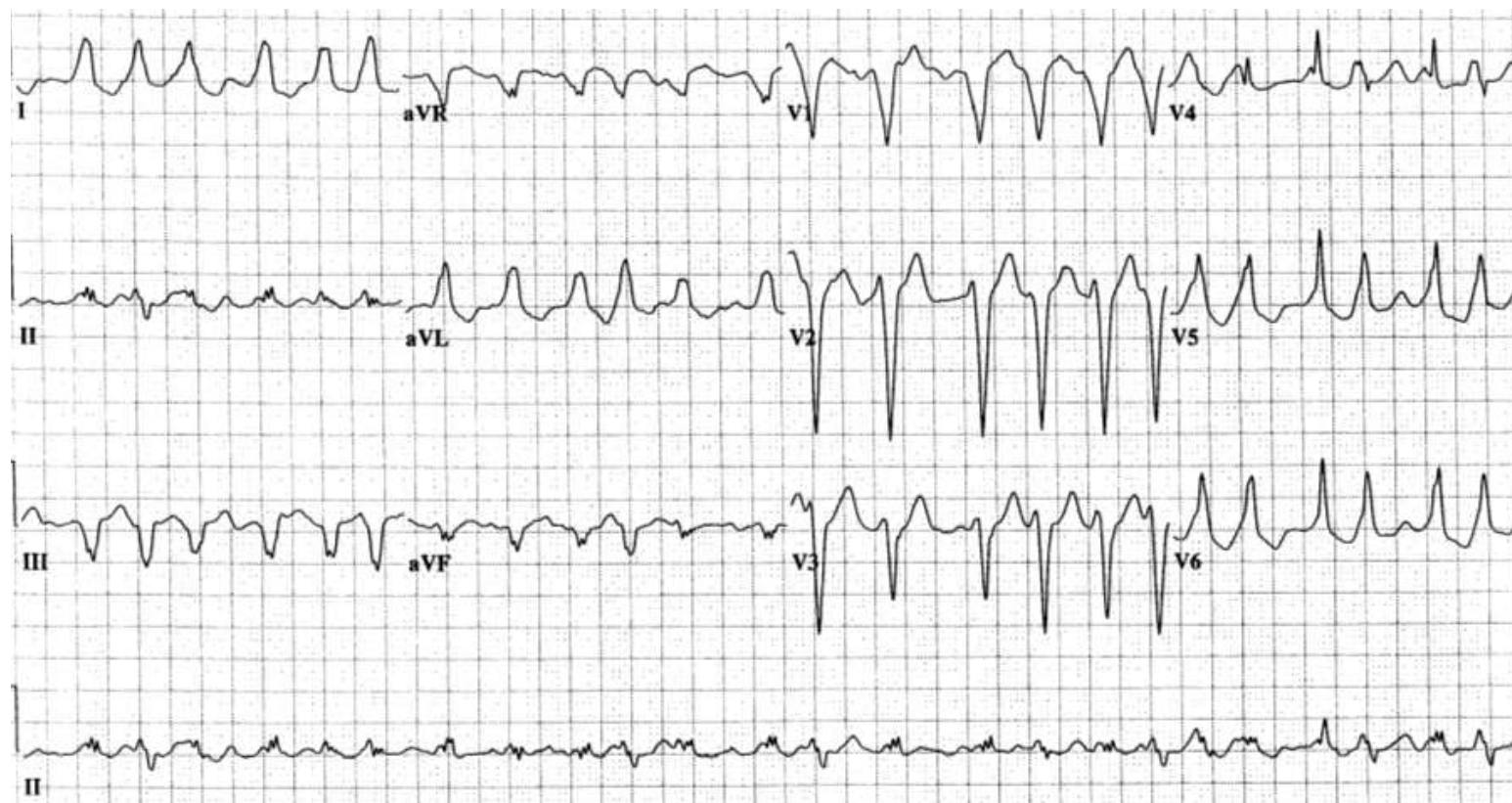
1. A 29 yo man presents after a syncopal episode.



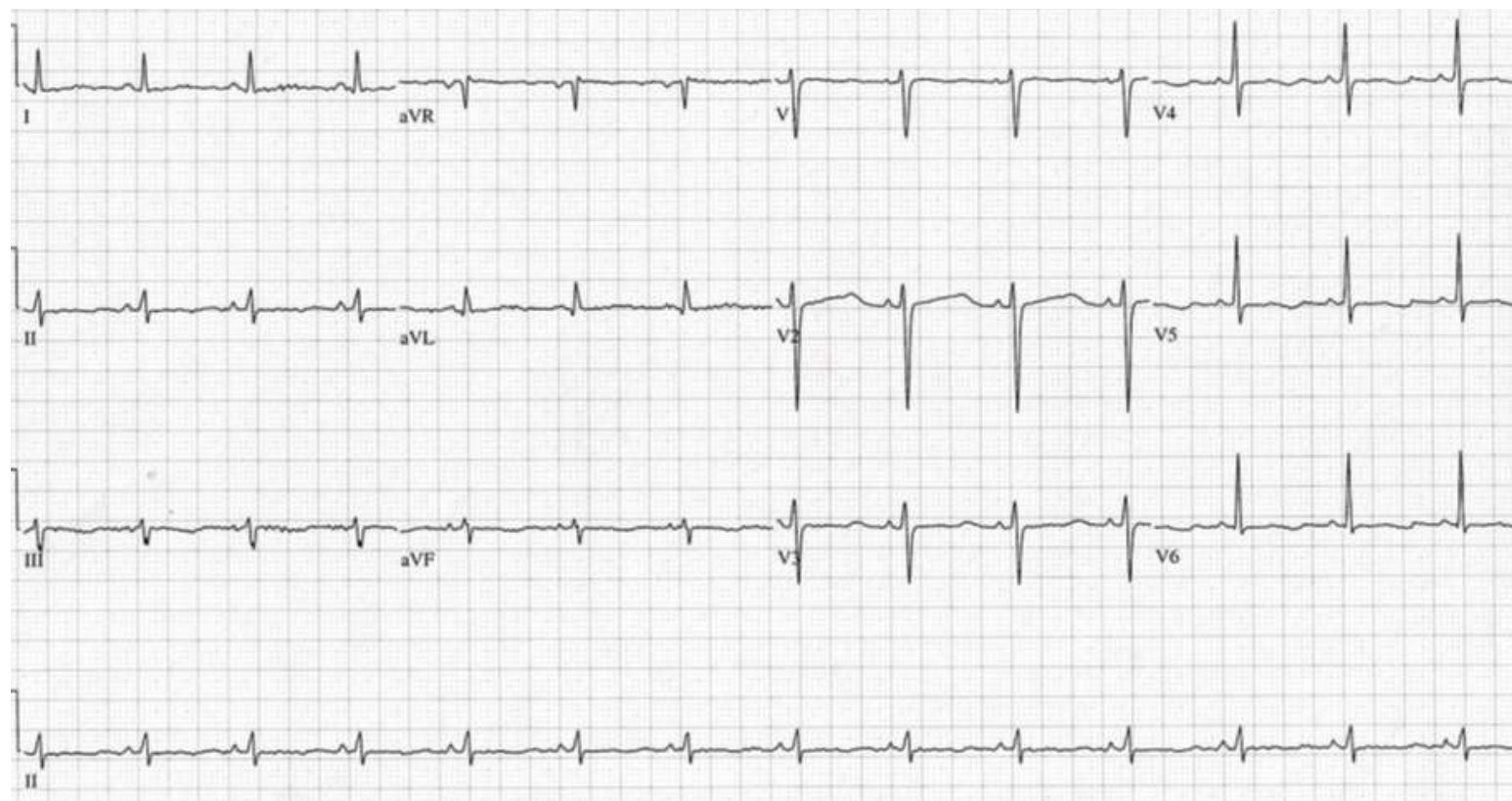2. 35 yo man presents after a syncopal episode.



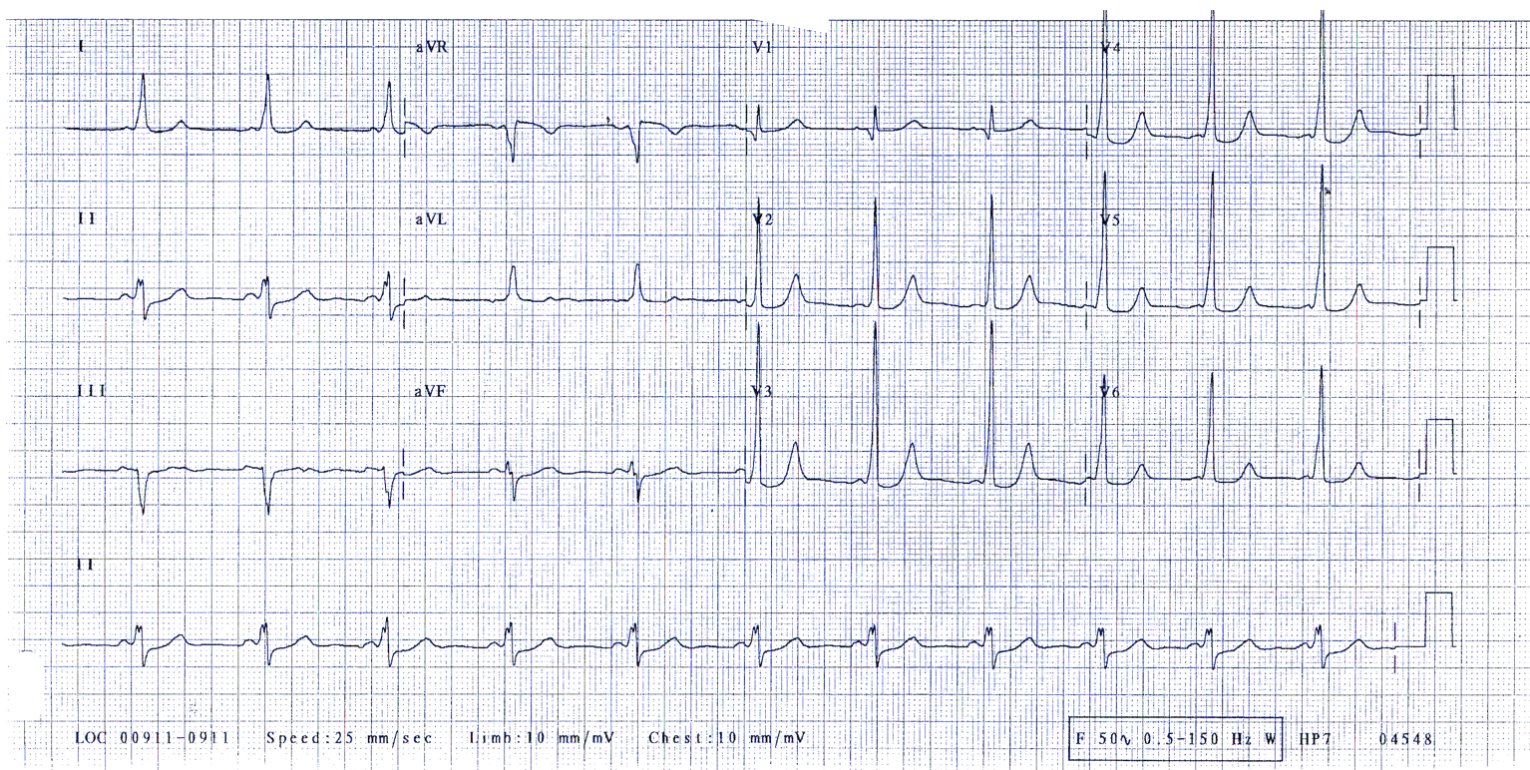
3. A 41 yo woman presents with palpitations



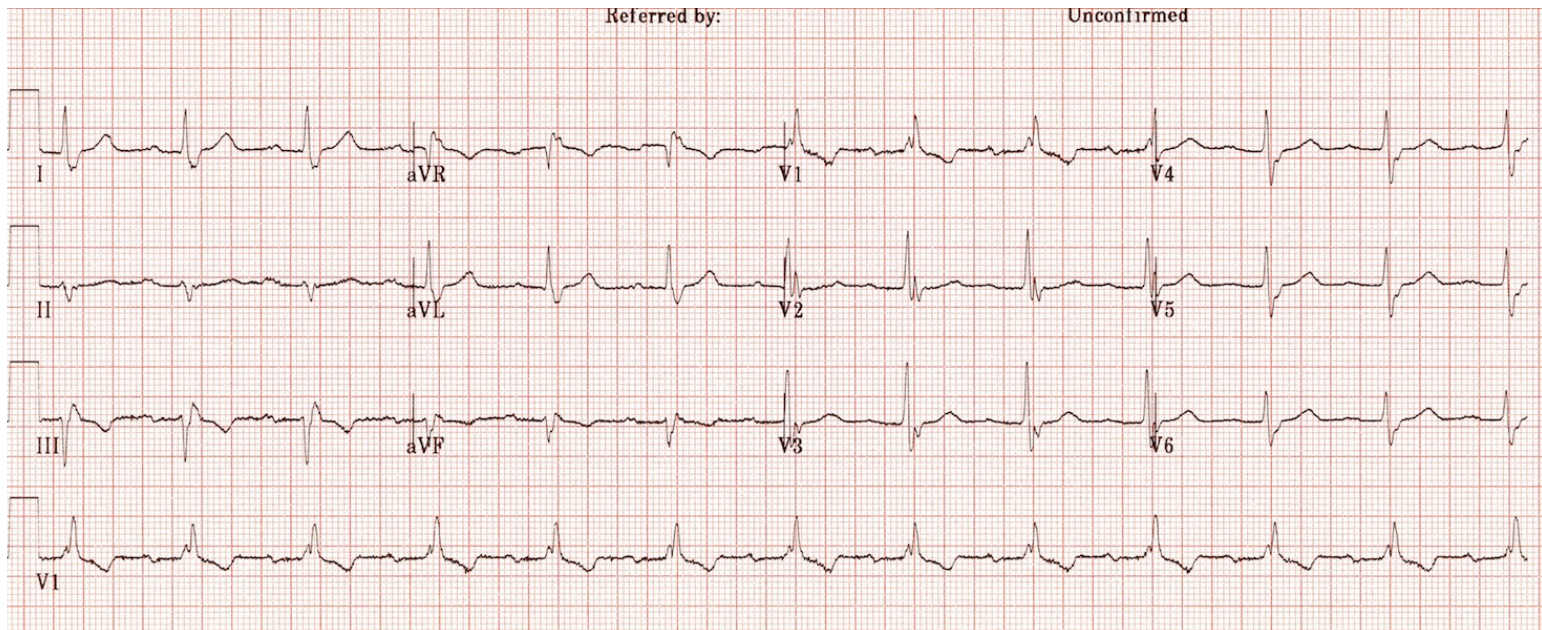
4. A 50 yo woman presents after a syncopal episode. She is on treatment for paroxysmal AF.



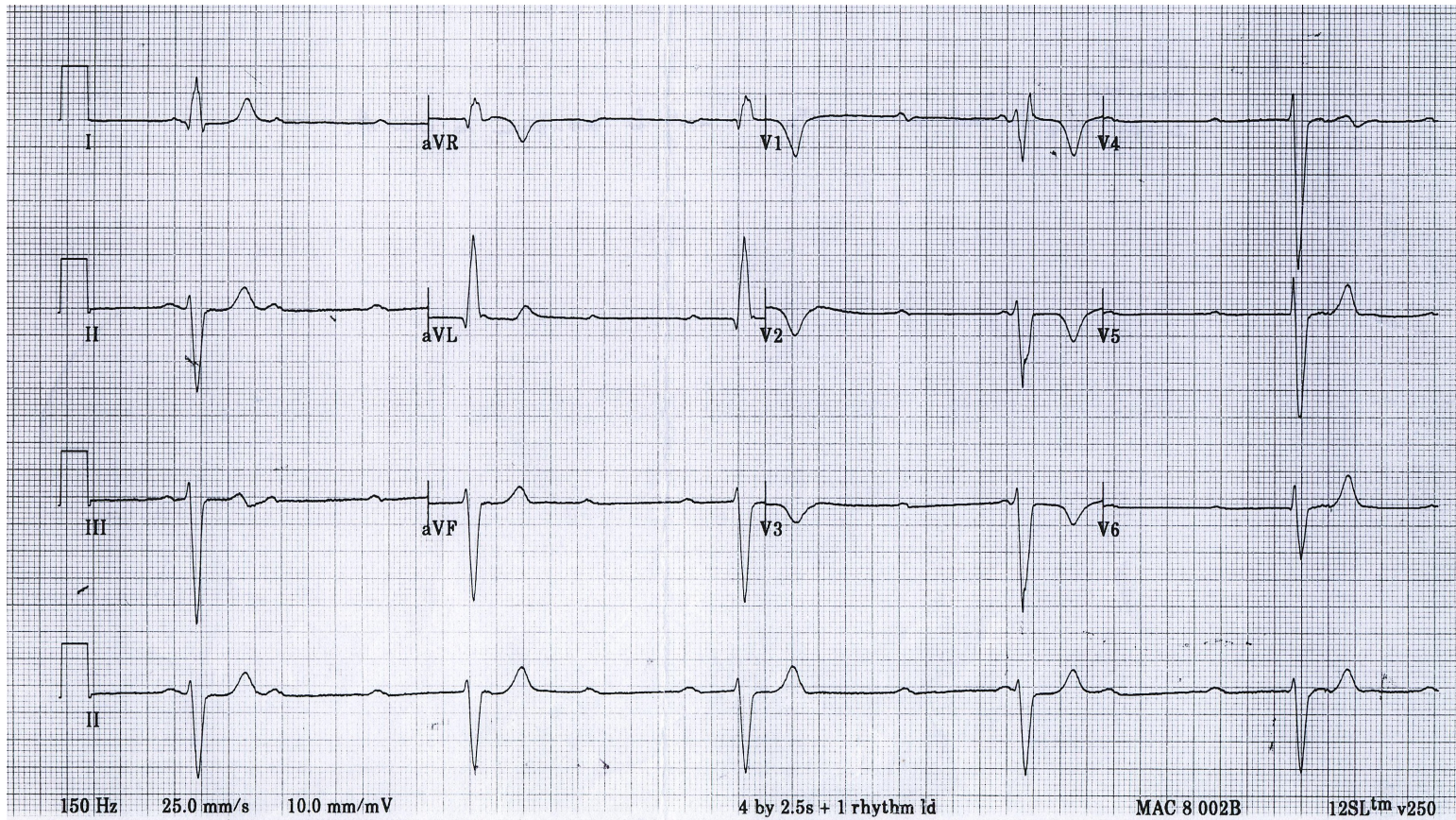
5. A 24 yo woman presents with atypical chest pain.



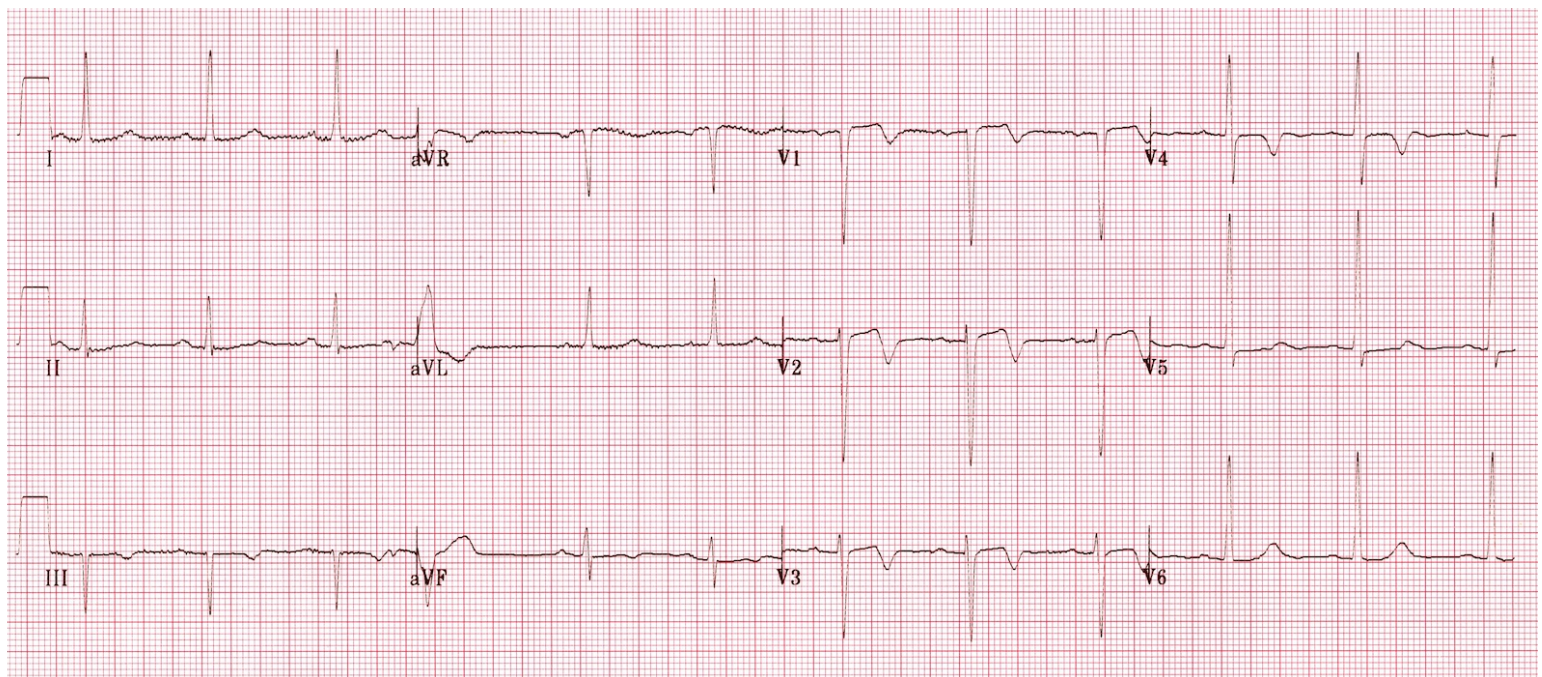
6. A 70 yo man presents with syncope.



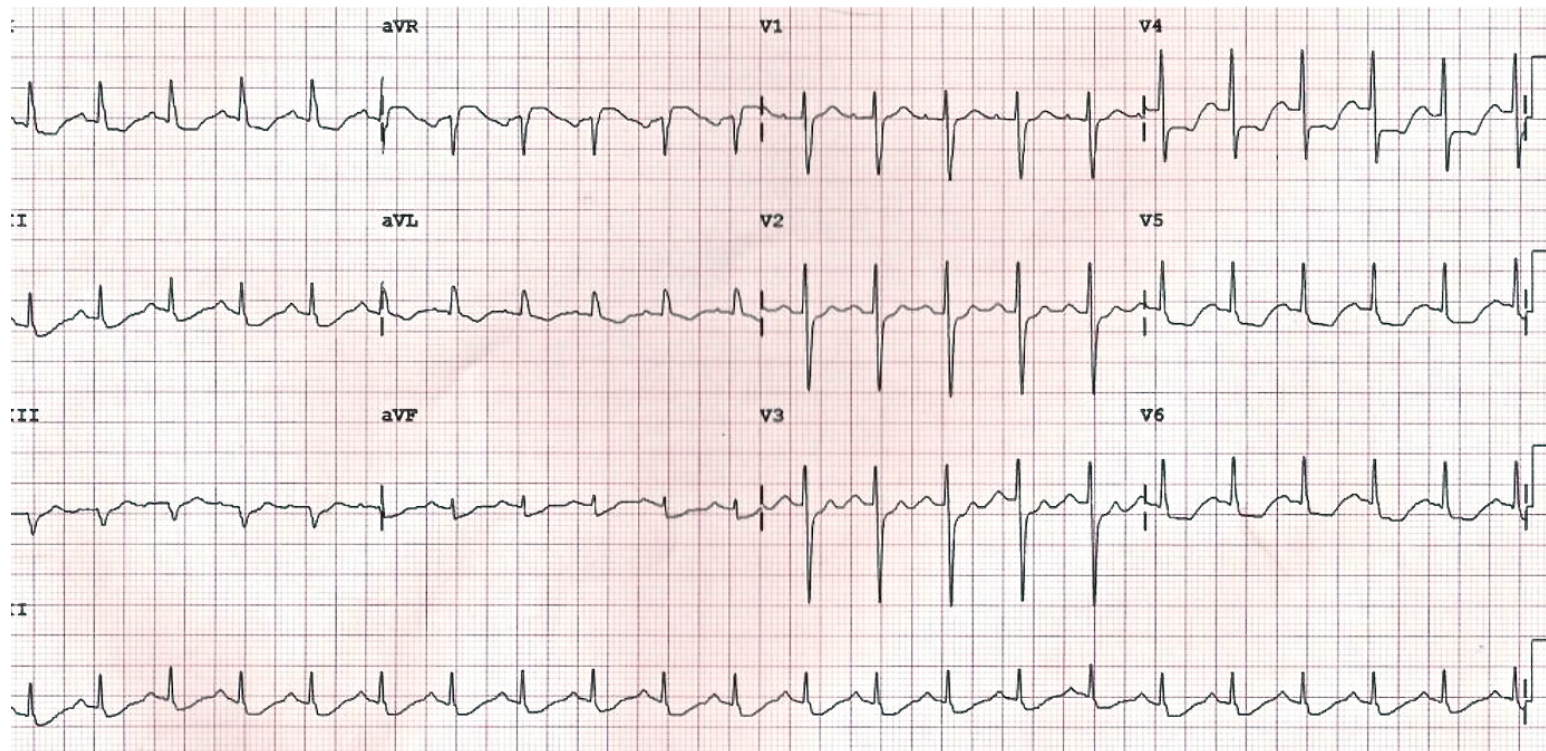
7. A 75 yo woman presents following a fall.



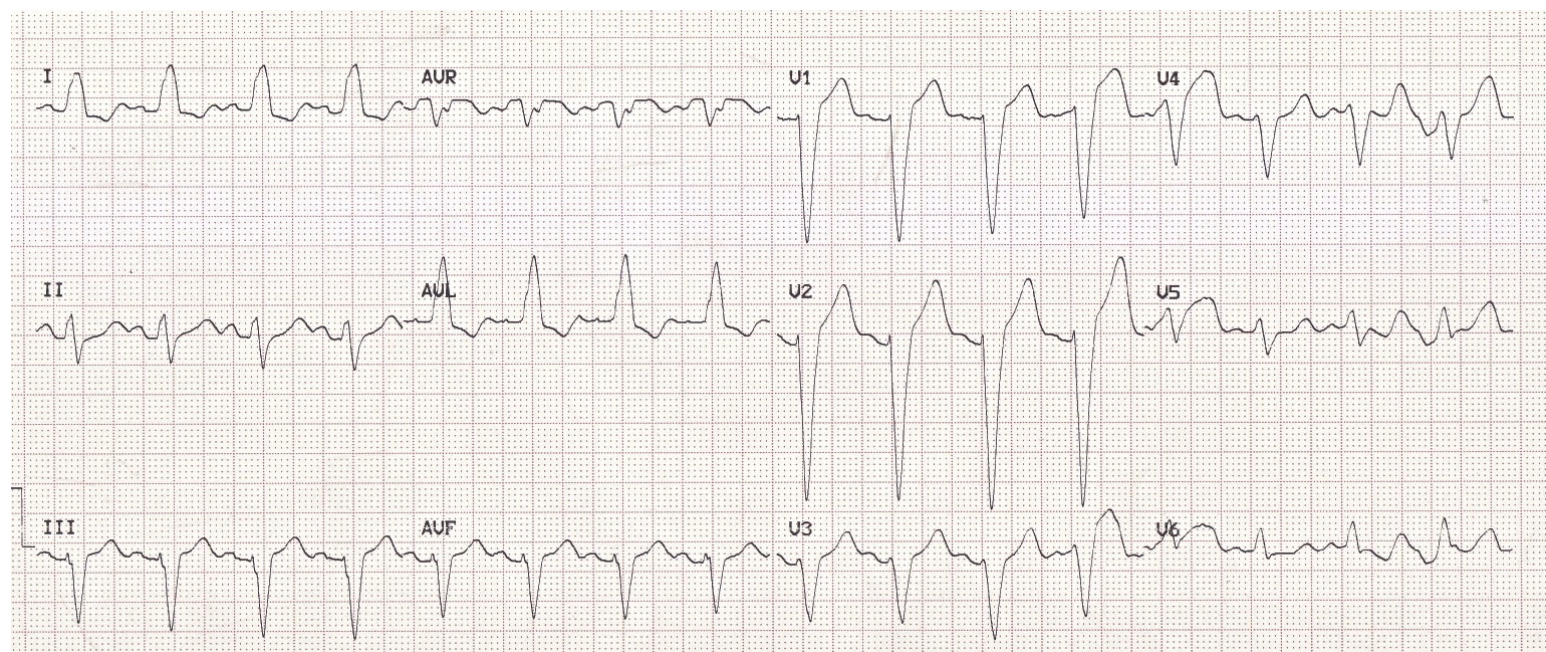
8. A 42 yo man presents with chest pain. This is his painfree ECG.



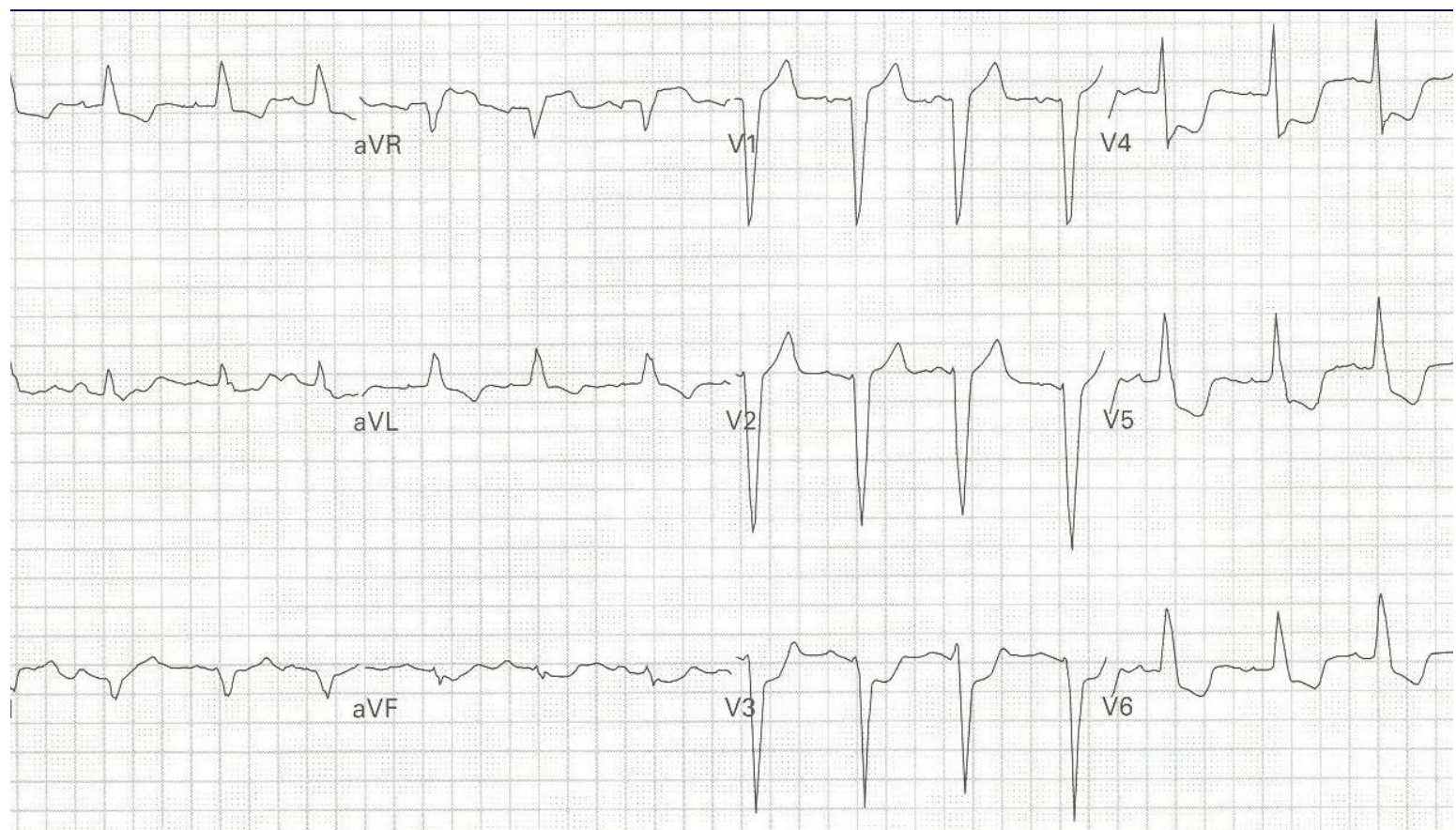
9. A 66 yo man with chest pain.



10. A 75 yo woman with chest pain and SOB



11. A 75 yo woman with chest pain and SOB



12. A 47 yo alcoholic with burning chest pain

