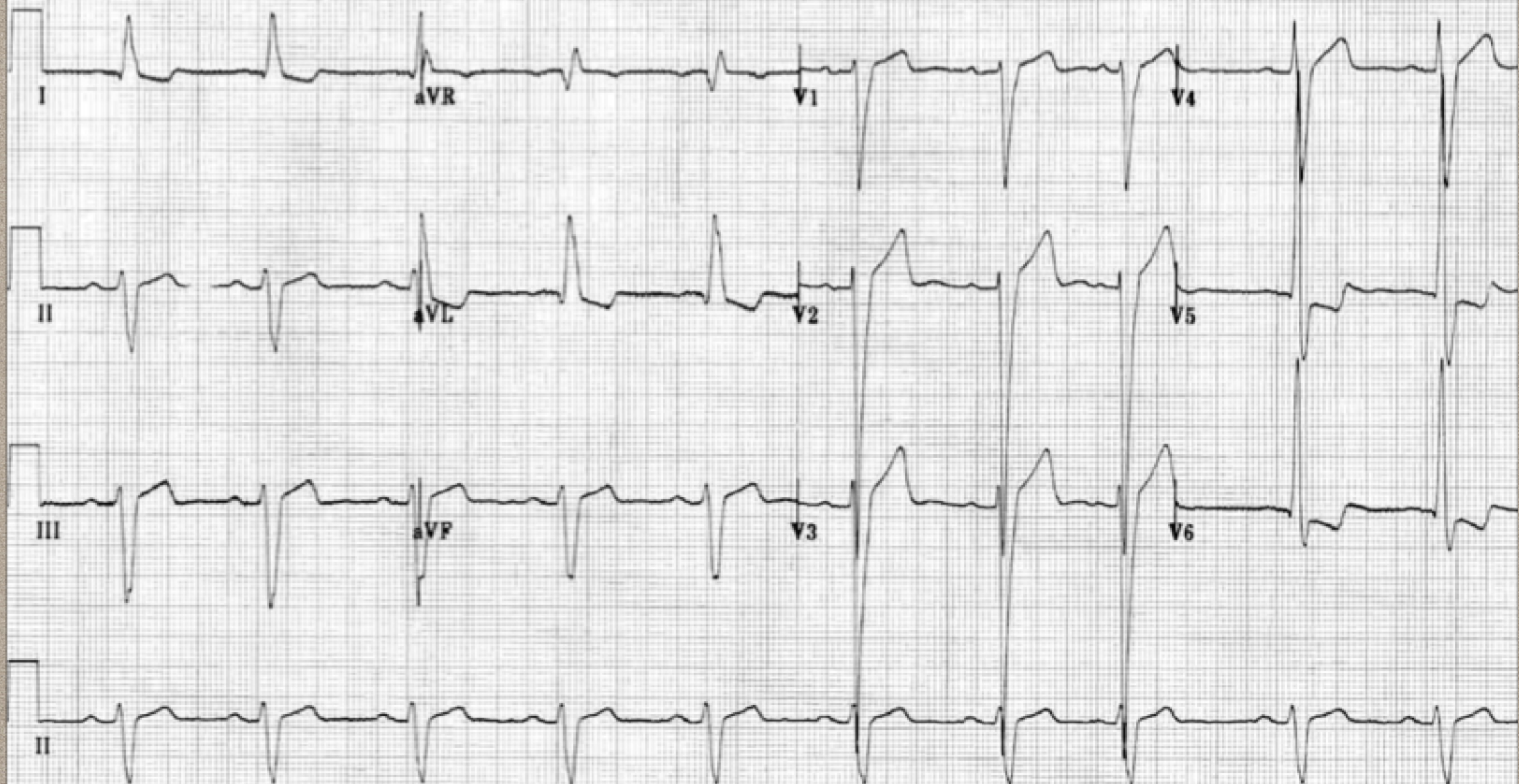


# **QUESTION 27**

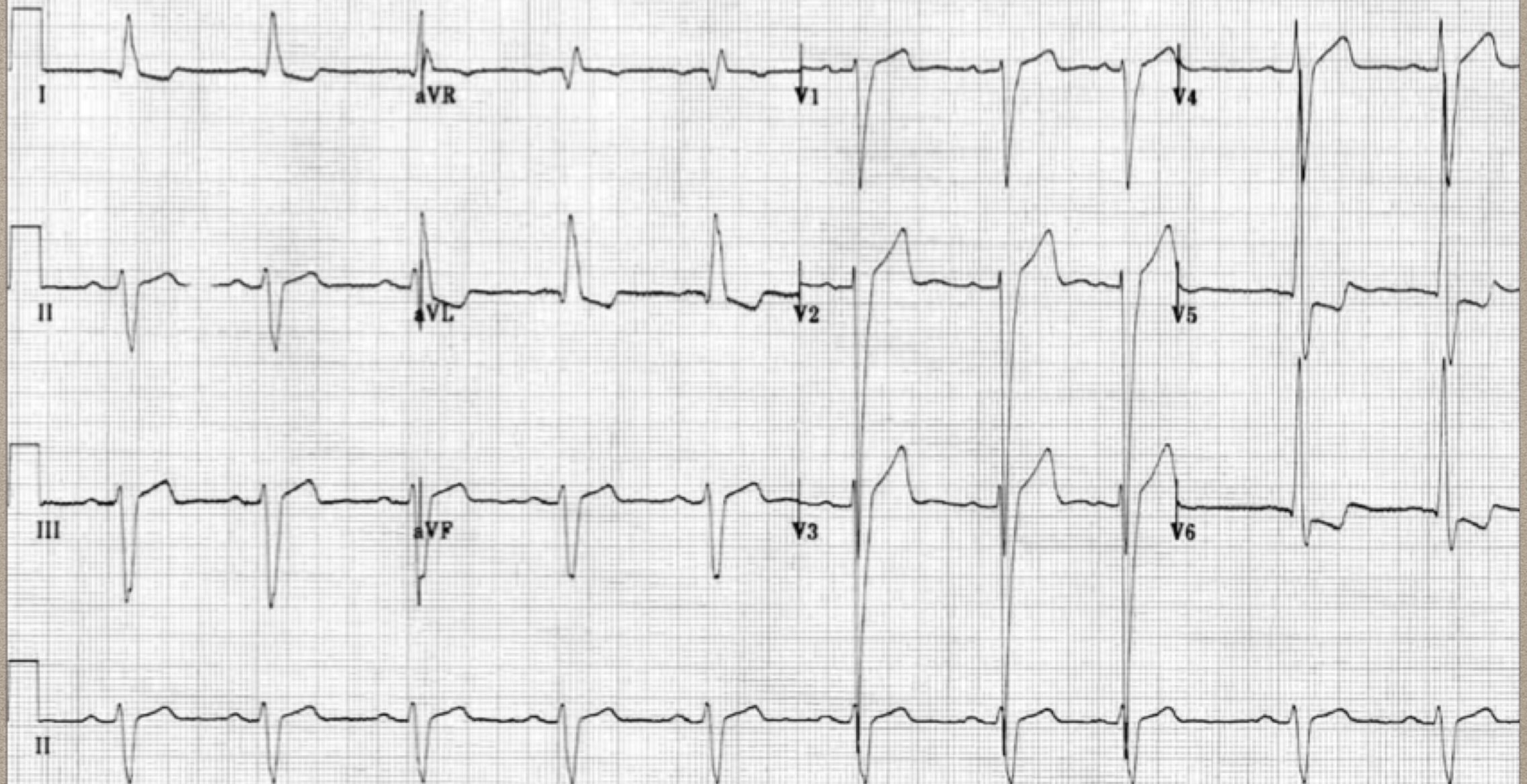
**FELLOWSHIP MOCK EXAM  
MONASH HEALTH, 2019.1  
PARYA FADAVI, ED PHYSICIAN  
CASEY HOSPITAL, MONASH HEALTH**





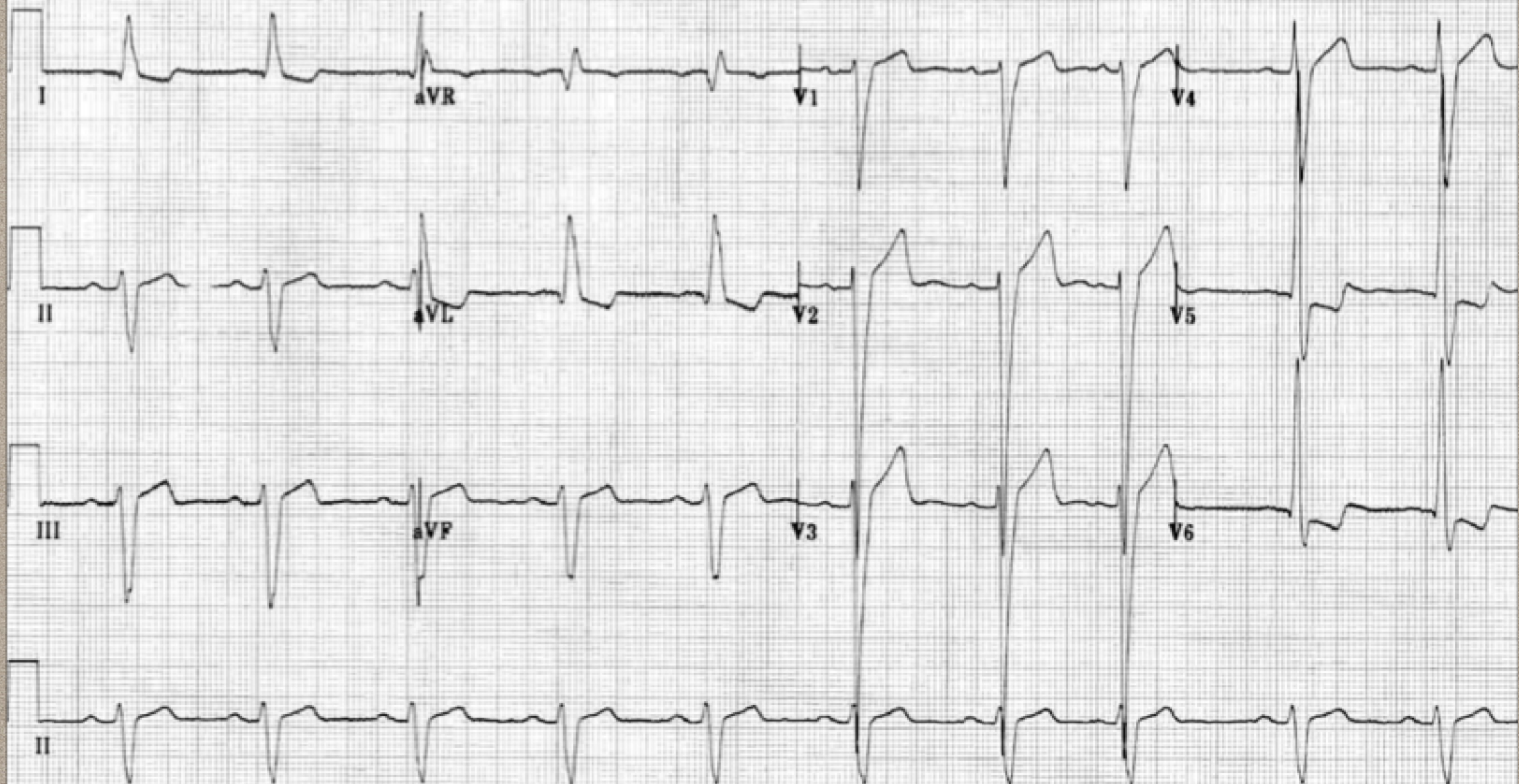
**A 68 y/o woman brought to your Emergency Department after a collapse at home when walking to the bathroom.**





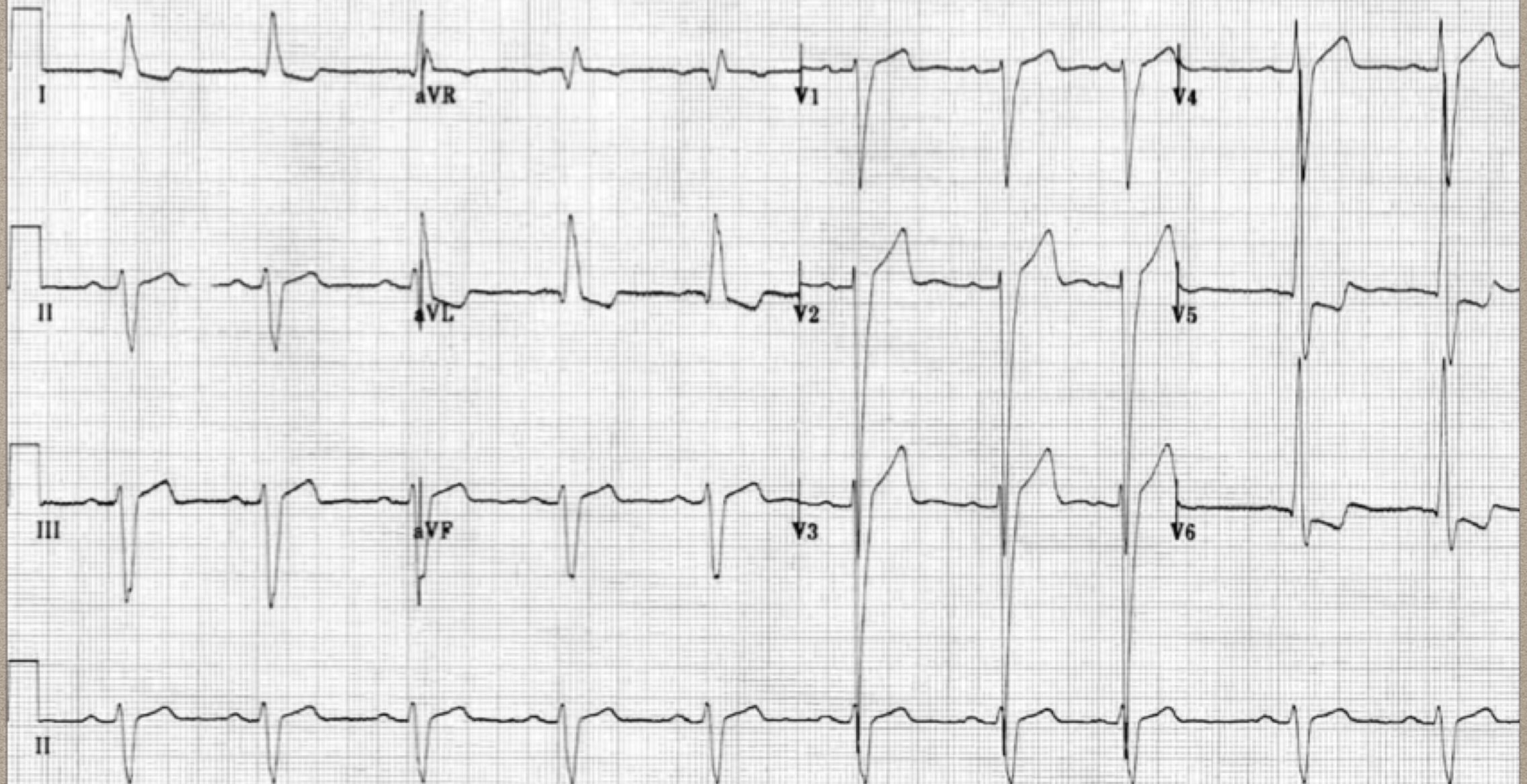
**1-List 4 abnormal findings on this ECG.(4 marks)**





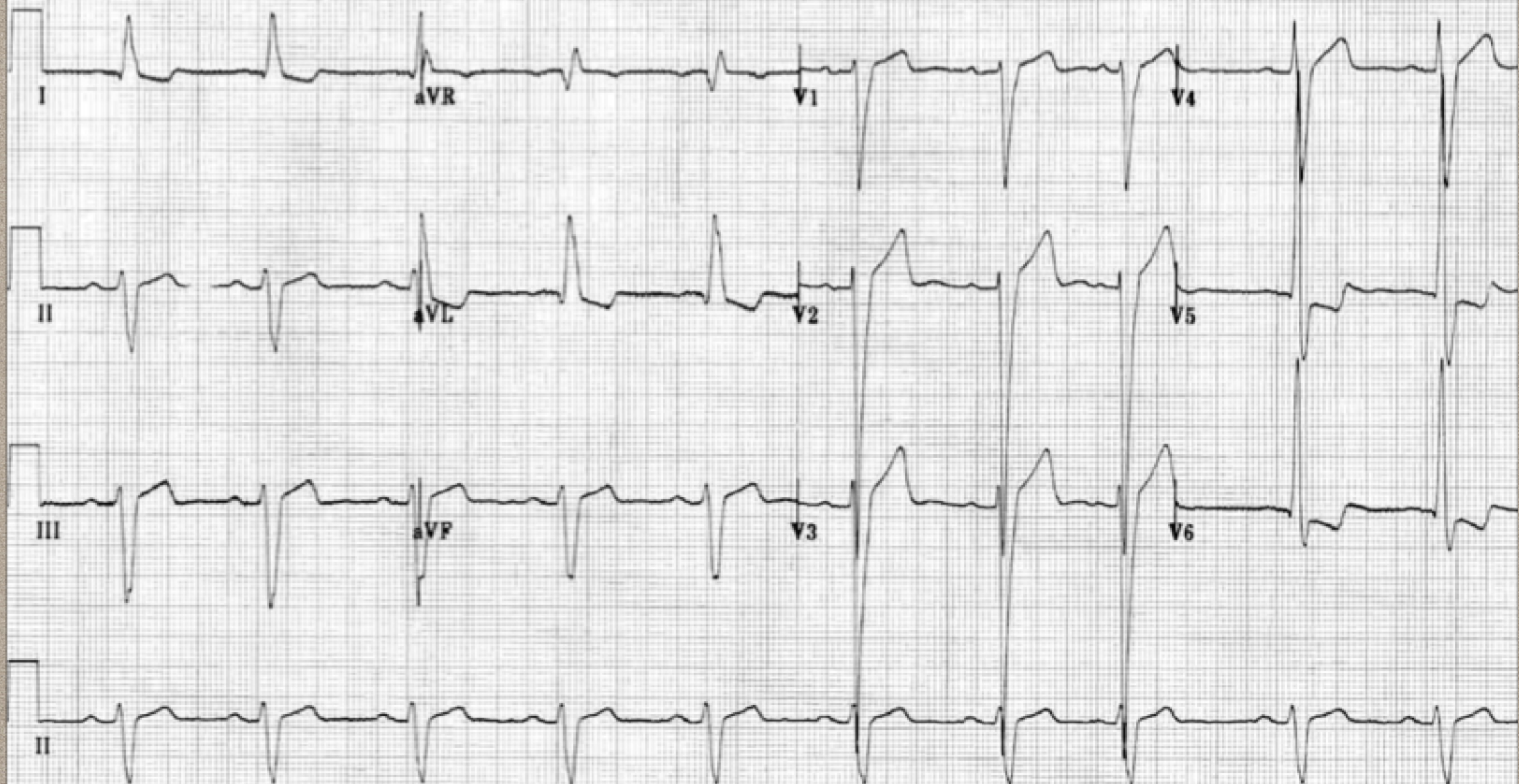
**1-Markedly increased LV voltages: huge precordial R and S waves that overlap with the adjacent leads ( $SV2 + RV6 \gg 35$  mm).**





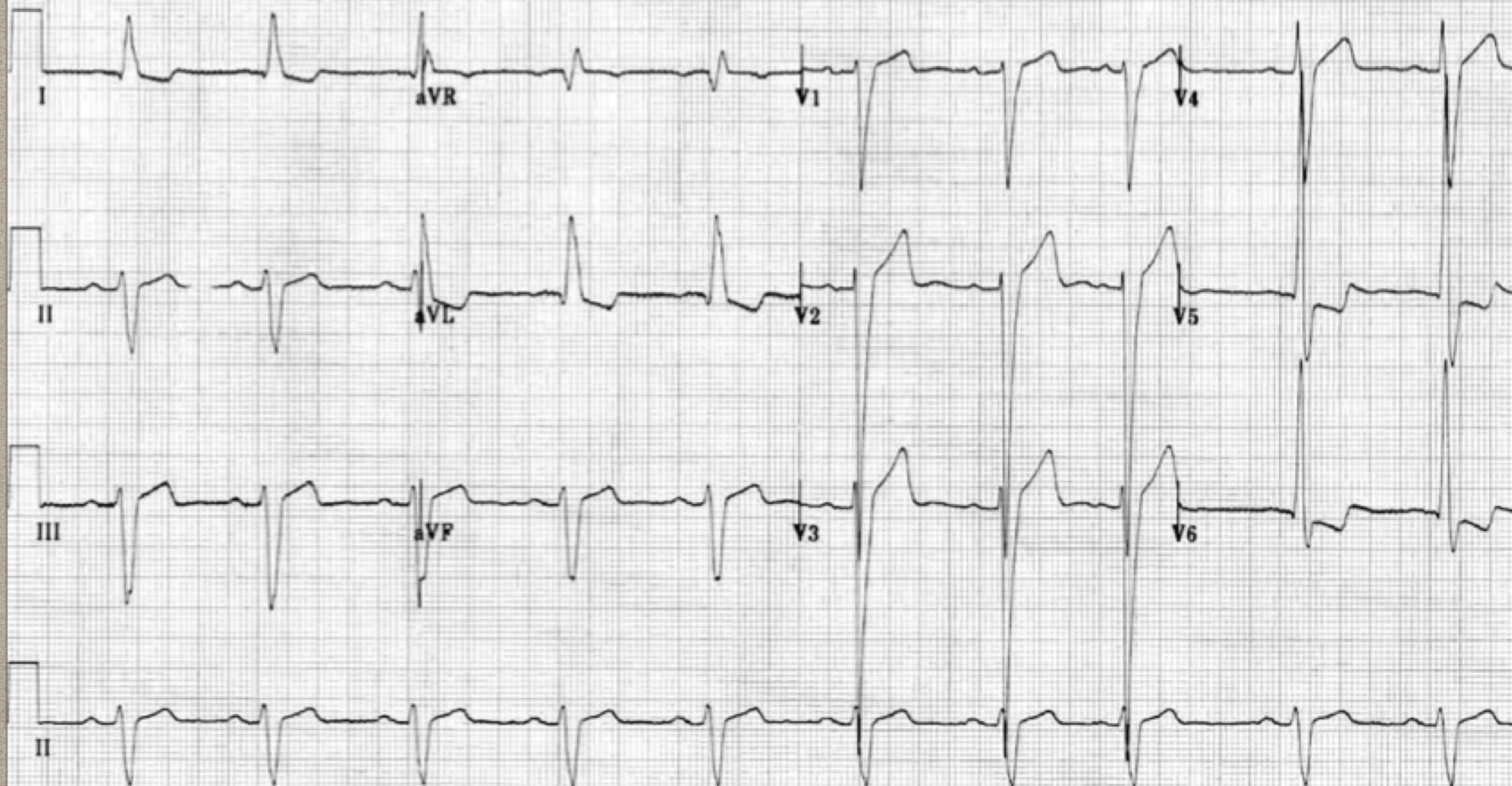
**2-R wave peak time > 50 ms in V5-6 with associated QRS broadening.**





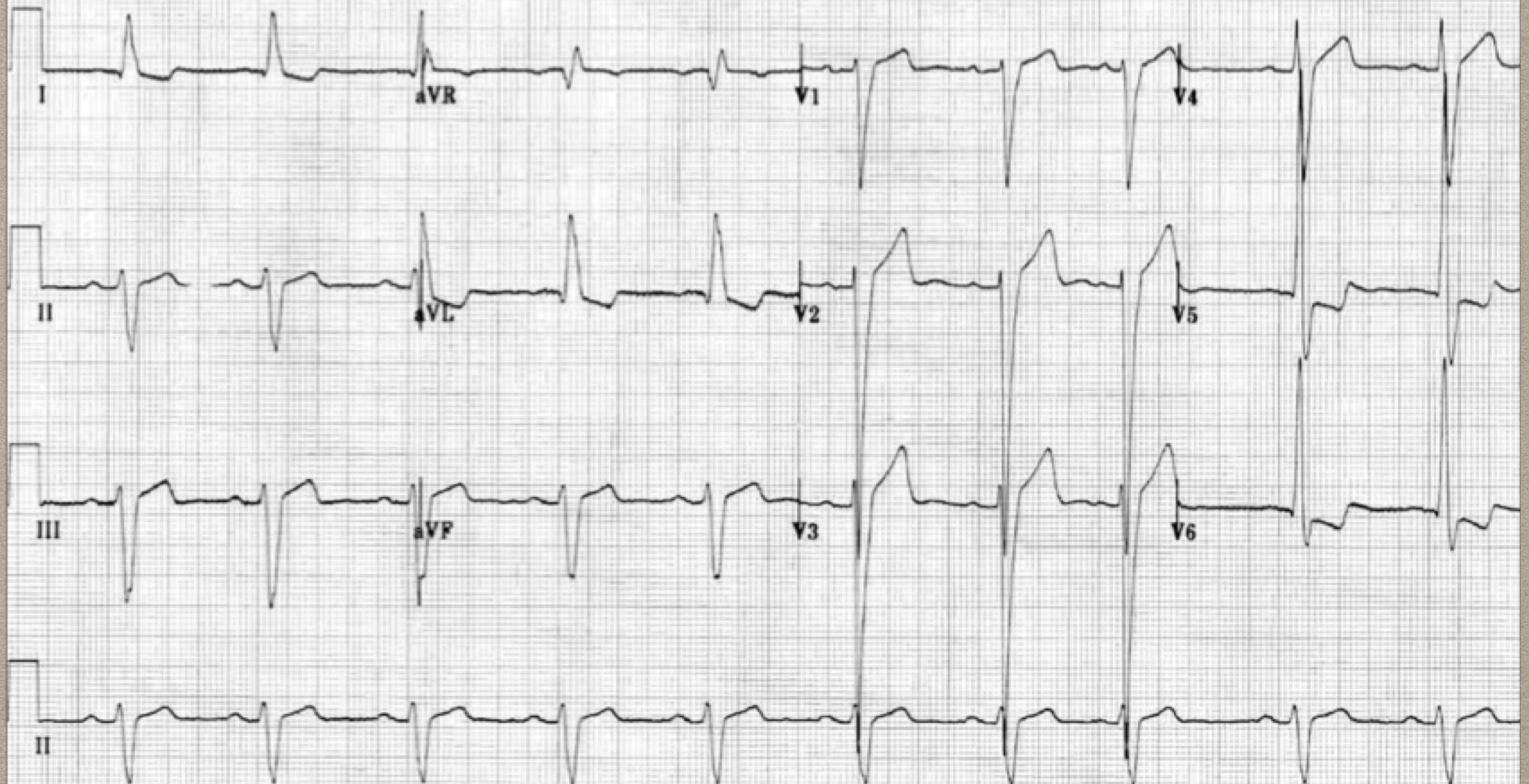
**3-LV strain pattern with ST depression and T-wave inversions in I, aVL and V5-6.**





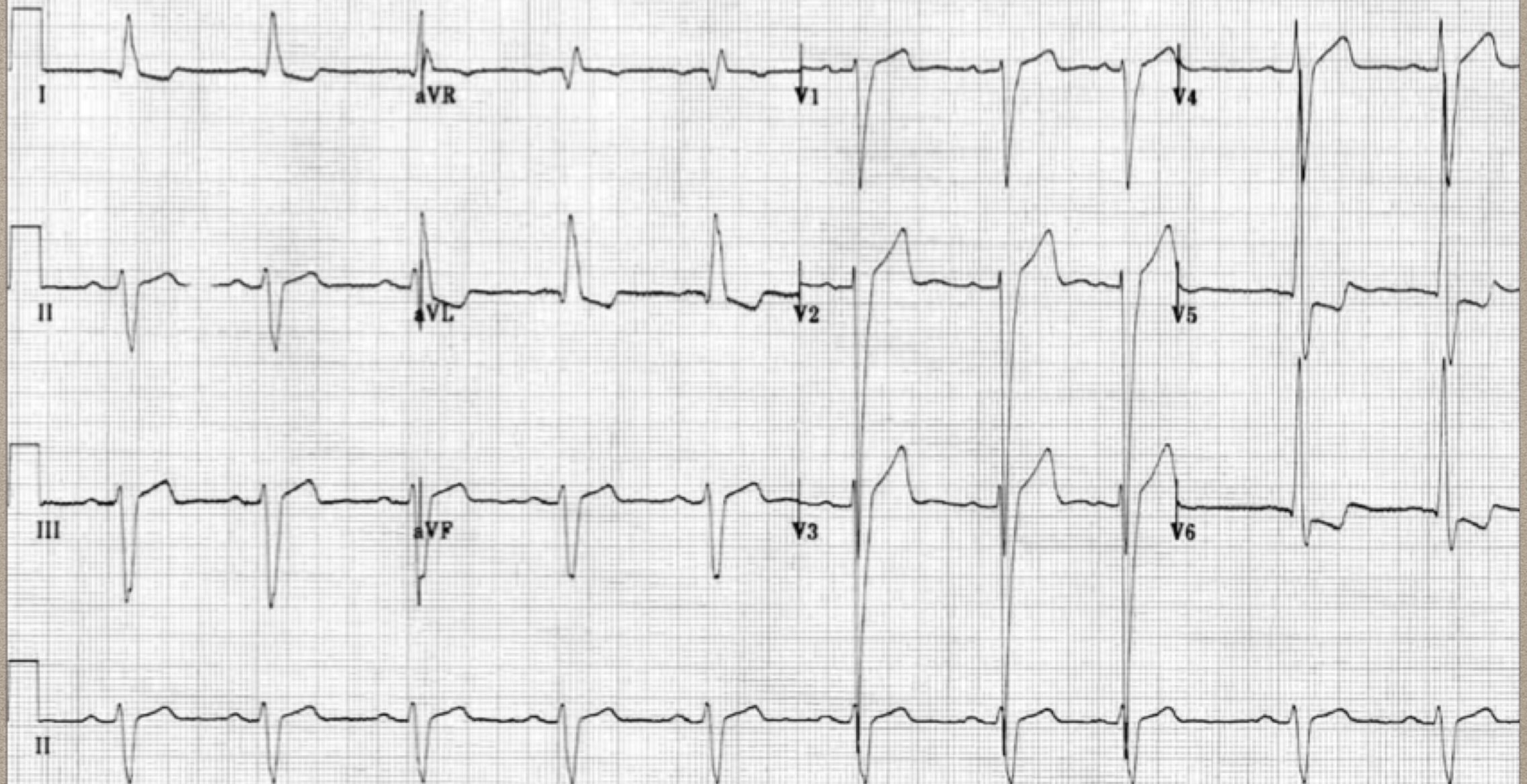
**4-ST elevation in V1-3.**





**5-Prominent U waves in V1-3.**





**6-Left axis deviation.**

**Other answers: LBBB, RAD, STD?, 1st degree AV block,**



- **Markedly increased LV voltages: huge precordial R and S waves that overlap with the adjacent leads (SV2 + RV6 >> 35 mm).**
- **R-wave peak time > 50 ms in V5-6 with associated QRS broadening.**
- **LV strain pattern with ST depression and T-wave inversions in I, aVL and V5-6.**
- **ST elevation in V1-3.**
- **Prominent U waves in V1-3.**
- **Left axis deviation.**



**2-list 3 key features on examination that you would seek given your ECG findings.(3 marks)**

- **HTN**
- **Ejection systolic murmur (A.S).**
- **Early diastolic decrescendo murmur(AI).**
- **Pancystolic murmur ( mitral regurgitation)**
- **Displaced apex**
- **Your answers: left ventricular heave??, postural hypotension**
- **S3,S4,Chest pain?/SOB?/hypoxia**



**List 3 possible findings in this lady's bedside echo.(3 marks)**

- **LVH**
- **Regional wall motion abnormality**
- **Aortic valve stenosis**
- **Aortic regurgitation**
- **Mitral regurgitation**
- **Other answers: LV enlargement, Apical hypokinesis**



**You decide to use this ECG as an aid in a teaching session for your registrars about syncope.**

**d) List six ECG features that are NOT on this ECG that you would teach your registrars to look for. (6 marks)**

- **1-HOCCM--Dagger like Q wave, LVH**
- **2-WPW--Delta wave, Short PR, Wide QRS**
- **3-ARVD--epsilon wave, T wave inversion**
- **4-Prolonged QT syndrome**
- **5- Trifasicular block, AV block( 2nd degree,mobitz type II,AV dissociation)**
- **6-Short QT**
- **7- Brugada --Coved ST elevation**
- **Other answers:1st degree AV block, De winter, ST elevation in aVR,S1Q3T3,**



# **RESULT:**

**Total Mark:16      Pass Mark: 10**

- **Highest Mark: 14,1 candidate**
- **Lowest: 0 ,4 candidates**
- **7 candidates passed.**
- **Pass rate:7/33 ~ 21%**



**GOOD LUCK!**