

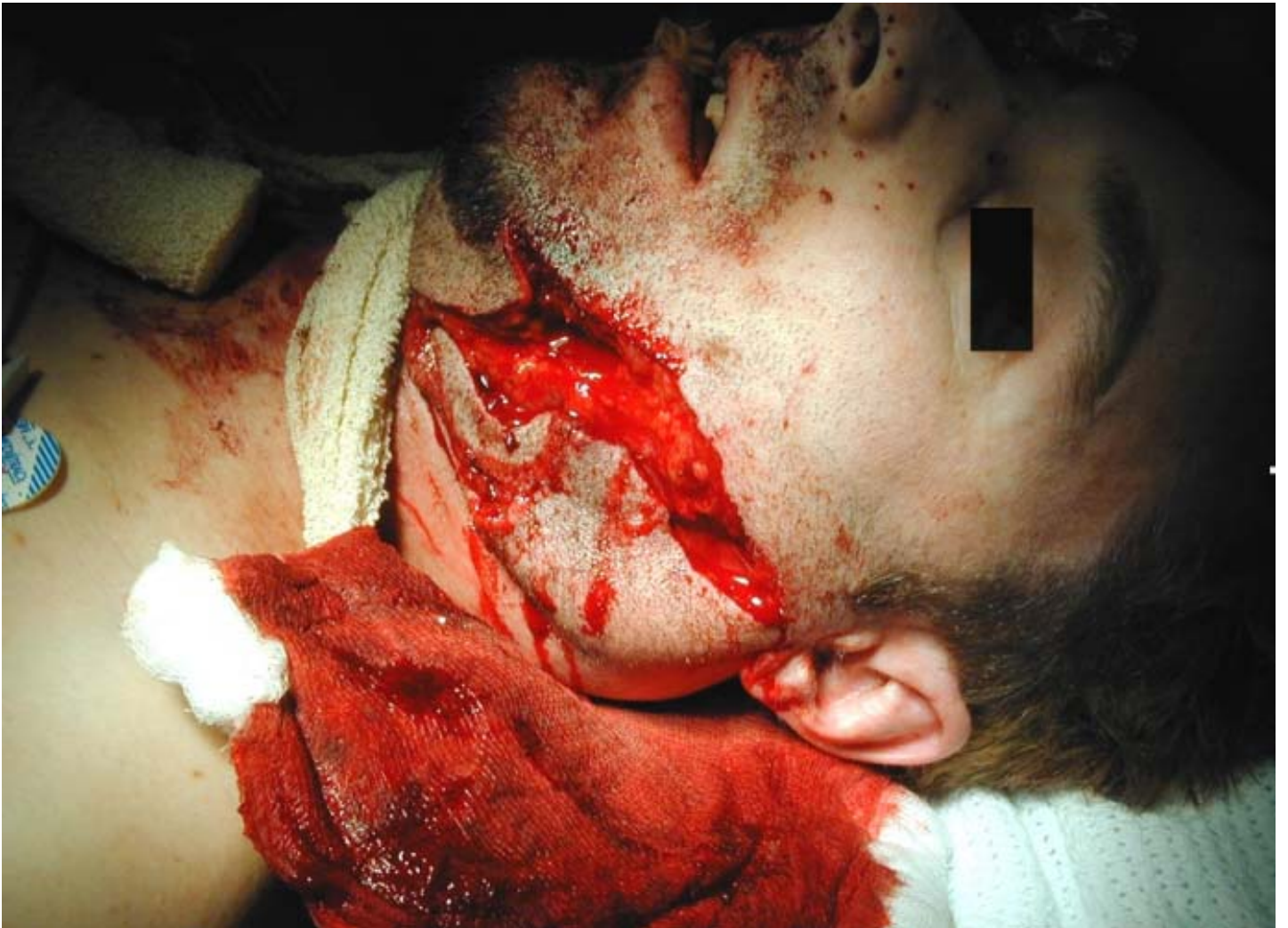**AUSTRALASIAN COLLEGE FOR EMERGENCY MEDICINE
FELLOWSHIP EXAMINATION**

Question 4

A 25 year old man has been brought in to your emergency department after sustaining a knife wound to his neck in an assault. His vitals signs and GCS are normal.

- a. Describe his photograph (50%)
- b. List the likely associated injuries (50%)

Question 4. Photograph



AUSTRALASIAN COLLEGE FOR EMERGENCY MEDICINE
FELLOWSHIP EXAMINATION
17 FEBRUARY 2010 - PART C

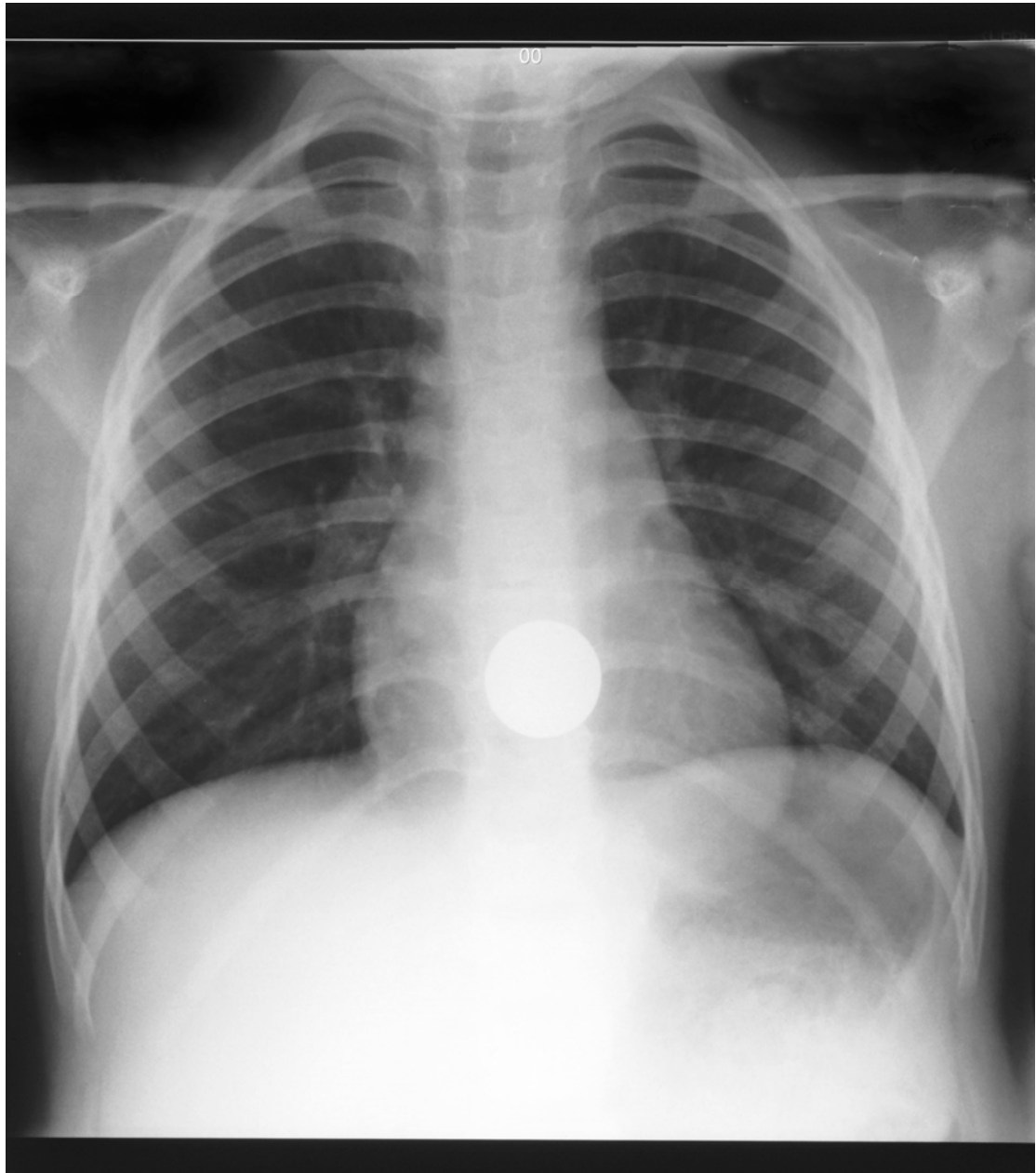
Question 5

A 4 year old boy presents to the emergency department following a choking episode at home 30 minutes previously.

An X-ray is performed.

- a. Describe and interpret his X-ray (30%)
- b. What factors would determine your further management (70%)

Question 5. X-ray



AUSTRALASIAN COLLEGE FOR EMERGENCY MEDICINE
FELLOWSHIP EXAMINATION
17 FEBRUARY 2010 - PART C

Question 6

A 64 year old man is being evaluated in your emergency department after an episode of chest pain which has now resolved.

His observations are:

BP	140/85	mmHg supine
RR	20	/min
O ₂ saturation	97%	room air

- a. Describe and interpret his ECG (50%)
- b. List the potential causes of this rhythm abnormality (50%)

Question 6. ECG

